Transactions on Machine Learning and Artificial Intelligence - Vol. 10, No. 1
Publication Date: February, 25, 2022
DOI:10.14738/tmlai.101.11805.
Daghistani, T. (2022). Using Artificial Intelligence for Analyzing Retinal Images (OCT) in People with Diabetes: Detecting Diabetic Macular Edema Using Deep Learning Approach. Transactions on Machine Learning and Artificial Intelligence, 10(1). 41-49.

Using Artificial Intelligence for Analyzing Retinal Images (OCT) in People with Diabetes: Detecting Diabetic Macular Edema Using Deep Learning Approach

Tahani Daghistani
King Saud Bin Abdulaziz University of Health Sciences
Ministry of National Guard Health Affairs, Riyadh, KSA

ABSTRACT

Medical imaging evolved rapidly to play a vital role in diagnosis and treatment of a disease. Automate analysis of medical image analysis has increased effectively through the use of deep learning techniques to obtain much quicker classifications once trained and learn relevant features for specific tasks, shown to be assessable in clinical practice and valuable tool to support decision making in medical field. Within Opthalmology, Optical Coherence Tomography (OCT) is a volumetric imaging procedure that uses in the diagnosis, monitoring and measuring response to treatment in eyes. Early detection of eyes diseases including Diabetic Macular Edema (DME) is vital process to avoid complications such as blindness. This work employed a deep convolutional neural network (CNN) based method for DME classification task. To demonstrate the impact of convolutional, five models with different Convolutional layers built then the best one selected based on evaluation metrics. The accuracy of model improved while increasing the number of Convolutional Layers and achieved 82% by 5-Convolutional Layer, Precision and Recall of CNN model per DME class was 87%% and 74%, respectively. These results highlighted the potential of deep learning in assisting decision-making in patients with DME.

Keywords: diabetic macular edema, OCT images, deep learning, CNN

INTRODUCTION

Medical imaging is one of the richest and most complex sources of information about patients, and its data is the primary diagnostic in many medical cases. With the increase in the data of medical imaging of various types, extracting and take an advantage of extracted information has become a major challenge, which calls for the intervention of artificial intelligence and the use of its tools [18]. Optical Coherence Tomography (OCT) is one of the medical imaging modalities, can be used to diagnose different eye diseases. Analyzing the captured images can be used for early diagnosis of several diseases included DME by identifying the structure of normal and diseased retina [5]. Various explainability methods have been developed and applied to medical imaging including ophthalmology, the applications of Deep Learning (DL) methods in ophthalmology is limited [11, 21].

Diabetic macular edema (DME) is a common complication of diabetic retinopathy (DR). Early detection and treatment is a vital step and essential to avoid complete blindness. Regular screening for early detection is a vital step to prevent complication and considered an initiative

to improve public health. However, it is an intensive labor and resource oriented task [20, 30]. Therefore, Strategies involving Artificial Intelligence (AI) could provide a solution to automate detection process of such diseases. Diagnostic imaging is a promising clinical application of AI to facilitate detection of a wide range of clinical cases. Utilization of Artificial Intelligence represent an opportunity for healthcare providers to improve health care outcome by strengthening predictive abilities [2]. Early detection using deep learning method is more reliable to determine the presence of an abnormality in images [23]. In recent years, deep learning (DL) have demonstrated remarkable performance in medical imaging problems, and attracted considerable attention [32]. One of the typical tasks is detecting abnormalities and classifying them into disease categories [12, 31].

Few research works focused on analyzing OCT images and separate the healthy images. The main goal of this project is develop an Artificial Intelligence solution that can help to classify OCT. To achieve our goal, Deep-Learning (DL) model developed to predict the risk of patients with DME. The outcomes would improve patient access to treatment and reduce pressures on time and resources in ophthalmology clinics [4].

RELATED WORKS

The computer vision algorithms evolved rapidly and have huge potential applications to help analyze images in Ophthalmology. Deep learning is an emerging technology have been applied for diagnosis process in different modalities including Optical Coherence Tomography (OCT) to assess various diseases such as diabetic retinopathy (DR) and Diabetic macular edema (DME). This section presents reviews of the previous studies as evidence for deep learning in ophthalmology [6]. Wu et al. developed deep learning model to detect the morphologic patterns of DME with high sensitivity and specificity (>90%) based on OCT images **[**30**].** Li et al. presented an ensemble model to classify diabetic retinopathy (DR) and diabetic macular oedem (DMO) using 8739 retinal fundus images. The deep ensemble model generated excellent performance comparing with ophthalmologists. The AUC of the model was 99%, sensitivity 92% and specificity 96% for DR, while AUC of 99%, sensitivity 93% and specificity 97% for DMO. Whereas ophthalmologists obtained sensitivity ranged from 85% to 94% and specificity from 91% to 97% for DR. While sensitivity ranged from 0.852 to 0.946, and specificities from 0.926 to 0.985 for DMO [14]. Tang et al. developed DL model to classify the presence or absence of DME of three-dimensional (3D) and 2D scans. They trained and validated (73,746) OCT images from three devices using convolution neural network (CNN) with residual network (ResNet). Excellent performance demonstrated of the model for the automated classification with AUC (>90%). Further classification performed using seven external datasets for testing, AUC was (>89%) across datasets [26].

Another deep learning model trained by Varadarajan et al. to predict Center-involved diabetic macular edema (ci-DME) using monoscopic fundus photographs. The model reached 89%, 85% and 80% for ROC–AUC, sensitivity and specificity, respectively. In addition to predicts the presence of subretinal and intraretinal fluid (AUC> 80%) **[**27]. Zhang et al. proposed a transfer learning algorithm to diagnose OCT images. The proposed model outperform traditional algorithms in dealing with low-quality data, it provide self-enhancement ability for edge detection to enhance data quality. The model achieved 94.5% accuracy, 97.7% sensitivity and 97% specificity on unseen data [33]. Singh and Gorantla proposed a novel Algorithm named DMENet, which built based on Hierarchical Ensemble of CNNs (HE-CNN). The proposed

methodology two-stages to automate the screening of DME. First, classify images based on presence or absence of DME then pass positive cases into second stage to label them based on severity. The model achieved 96.12%, 96.32%, 95.84%, and F−1 score of 96% for Accuracy, Sensitivity, Specificity and F−1 score, respectively [22]. Wang et al. proposed a novel algorithm named as SBGFRLS-OCT algorithm for the segmentation and detection of DME in OCT image. The algorithm built based on the K-means clustering algorithm and improved Selective Binary and Gaussian Filtering regularized level set (SBGFRLS). Results showed that the precision was 97.7%, sensitivity 91.8%, and specificity 99.2% [29]. Li et al. classified Retinal disease in optical coherence tomography (OCT) images using ensemble approach based on improved residual neural network (ResNet50). The model achieved 97% accuracy, 96%, sensitivity, and 98.5% specificity. The result is comparable to the ophthalmologists with clinical experience [13]. Diabetic macular edema (DME) classification performed by Perdomo et al. using Convolutional Neural Network (CNN). OCT-NET built to automate diagnosis of DME based on OCT volumes. They have applied a leave-one-out cross-validation strategy and obtaining an accuracy, sensitivity, and specificity of more than 90%. [17]. Chan et al. reported an accuracy of 96%, in recognizing Spectral Domain Optical Coherence Tomography (SD-OCT) through transfer learning. Initially, the input image is pre-processed, including filtering and cropping, to obtain better classification performances. Later, features extracted using CNN of AlexNet. Later then images classified using SVM classifier [3].

METHODOLOGY

The steps of the modeling process described in the following subsections with details of each step.

Dataset and Feature Engineering

The dataset downloaded from the Kaggle https://data.mendeley.com/datasets/rscbjbr9sj/2 [9]. A total of (3,500) OCT images included in this dataset. OCT images were collected from a study of adult patients from the Shiley Eye Institute of the University of California San Diego, the California Retinal Research Foundation, Medical Center Ophthalmology Associates, the Shanghai First People's Hospital, and Beijing Tongren Eye Center between July 1, 2013 and March 1, 2017. The ratio of splitting the original dataset (3,500 images) is 50/20/30. Meaning training data made up of 50% training (1,960 images) then devote 20% to the validation set (490 images) to provide an unbiased evaluation of a model that fit on the training dataset while tuning hyperparameters of the model. Test dataset made up of remaining 30% (1,050 images) to evaluate the accuracy of the model on unseen data.

The preprocessing consisted of resize image to form a base size for all images fed into algorithms, the OCT images were resized into 224 × 224 pixel. Classic augmentation techniques like flips and rotations applied to each image in the training set without manually processing each image. Finally normalize all input images, an intensity value of 255 applied to remove saturated pixels.

Deep Learning Algorithm

Classification is the most widely used technique for machine learning, especially in prediction models. The machine learning algorithm used for solving image data challenge in this study is Convolutional Neural Networks (CNN) [31]. Convolutional Neural Network (CNN) is a deep learning algorithm for images classification, which perfectly handle this type of 2D images. It

deals with an input image as array of pixels present (Height x Width x Dimension). CNN is a powerful neural network that uses filters to extract/detect features from images in a way that position information of pixels is reserved [1, 6]. Technically, to train and test CNN model, each input image pass through one or more convolution layers with filters (Kernals), Pooling, fully connected layers and apply activation functions to classify an object with probabilistic values between 0 and 1 [24].

Activation function named Rectified Linear Unit (ReLU) automate extracting features by capture the nonlinearity of the image. The negative value present by zero, else the value itself. Other non-linear functions such as "tanh" or "sigmoid" are available but ReLU used because it performed well than the other two. Moreover, filter is placed top left of each image and multiplied with value on same indices. Then, all results summed and present as matrix as output. Then filter slips to place at right of image, whole processes repeat again. Sigmoid function used in many machine learning applications and placed as the last layer of the model. It convert the output of the model into a probability score and make it easier to interpret [15, 28]. The main process of pooling layer is reducing parameters by detect attributes invariant to scale or orientation changes. Thus, reduce computation process and prevents overfitting [25]. After the previous step convolutional and pooling, flatten applied on pooled feature and turn it one-dimensional to pass through fully-connected layer (Dense layer) where learning process start [1, 24]. An epoch is how many times the model trains on our whole data set. Batch can be explained as taking in small amounts, train and take some more. Each epoch must finish all batch before moving to the next epoch. The number of training epochs treated as a hyperparameter and train the model multiple times with different values, then select the number of epochs that result in the best performance on the train. . Each epoch must finish all batch before moving to the next epoch [10, 24]. Finally, Early Stopping used to reduce the computer calculation, running time and avoid overfitting. The model at the time that model stop leaning and no increase in the performance rate, thus, training model is stopped in order to have good generalization performance [10]. To demonstrate the impact of convolutional, five models with different Convolutional layers built then the best one selected based on evaluation metrics.

Model Evaluation and Selection

The dataset will divide into three sets: the training set for the development of the model, validation set to fine-tune your model until satisfied with its performance and the test set for evaluate the model. Matrices that used to select the best model are:

- Confusion Matrix
  - Accuracy
  - Precision: the percentage of visits that predicted normal, how many of them are actual normal. Precision is an excellent metric to determine when the costs of False Positive is high.

$$\text{Precision} = \frac{\text{True Positive}}{\text{True Positive+False Positive}} \quad (1)$$

  - Recall: the percentage the actual normal visits our model predicts through labeling it as normal (True Positive). The recall is a good metric to select the best model when there is a high cost of False Negative.

$$\text{Recall} = \frac{\text{True Positive}}{\text{True Positive+False Negative}} \quad (2)$$

- F-measure:

$$\text{F-score} = 2\ x\ \frac{\text{precision}*\text{recall}}{\text{percision+recal}} \quad (3)$$

- Area Under the ROC curve (AUROC)
- Loss to evaluate and diagnose model optimization.

RESULTS

To leverage deep learning as a solution to detect DME, we propose developing a CNN model trained on OCT images, using Normal and DME diagnoses derived as labels. Five CNN models developed with different convolutional layers to classify OCT images. Models Consist of input layers, two hidden layers, and one output layer with sigmoid as activation function. Table1 shows the performance of the CNN models on test dataset. The best performing model was the CNN model with5-Convolutional Layer. It achieved better among all metrics to the CNN with fewer layers. Although the improvement in the performance among all metrics, precision and recall due to balanced dataset. Table2 shows the performance per class of the models on the test dataset. In this scenario, the best performing model was the 5-Convolutional Layer. It achieved better precision and recall per class compared to models with fewer layers. The model with 4-Convolutional Layer was the second-best model, while model with only 1-Convolutional Layer was the lowest one.

Table1: The Performance of the Models on the Test Dataset

	Accuracy	precision	recall	f1-score	AUC
5-Convolutional Layer	82%	82%	82%	81%	82%
4-Convolutional Layer	79%	79%	79%	79%	79%
3-Convolutional Layer	74%	75%	74%	74%	75%
2-Convolutional Layer	74%	74%	74%	74%	74%
1-Convolutional Layer	63%	70%	63%	60%	63%

Table2: Precision and Recall Per Class for the Models on the Test Dataset

	precision	recall
DME	87%	74%
Normal	77%	89%

The below two plots (Figure 1), present the accuracy and loss of training and validation using a fixed learning rate of 1e-4 and 20 epochs for the best model. The training accuracy was linearly increasing with decreasing loss. As well increasing the accuracy of validation and decreasing loss. There is increasing in gap between train and validation loss to avoid

inconsistencies between train and validation. Although we defined maximum 20 epochs for training, the training was stopped as improvement in both accuracy and loss were stopped.

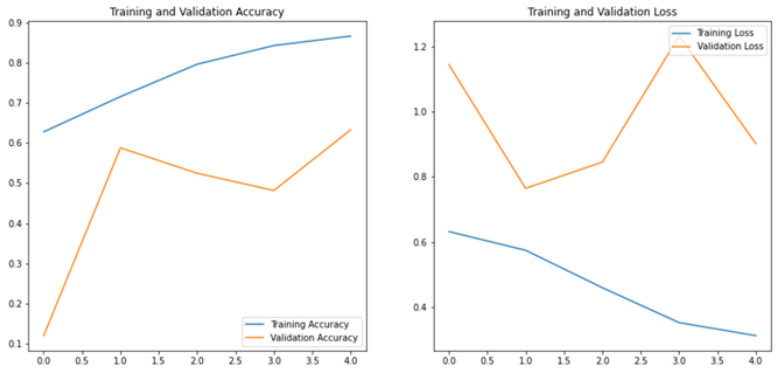

Figure 1: Accuracy and loss for training and validation sets

Figure 2 shows the improvement in accuracy among five model with increasing the number of convolution layers. Figure3 shows the five AUC for predicting the development of Diabetic Macular Edema were 63%, 74%, 75%, and 79%. The best AUC was 82% for the best model. Model performance continues to increase with increased CNN layers, suggesting that the accuracy of predicting DME will likely improve if more data used to train the model.

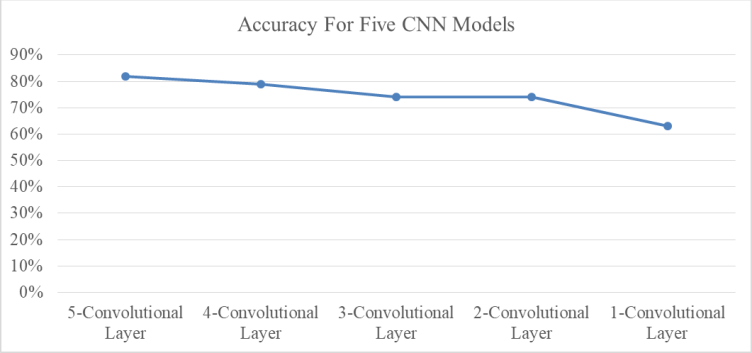

Figure 2: The Accuracy achieved for five CNN models

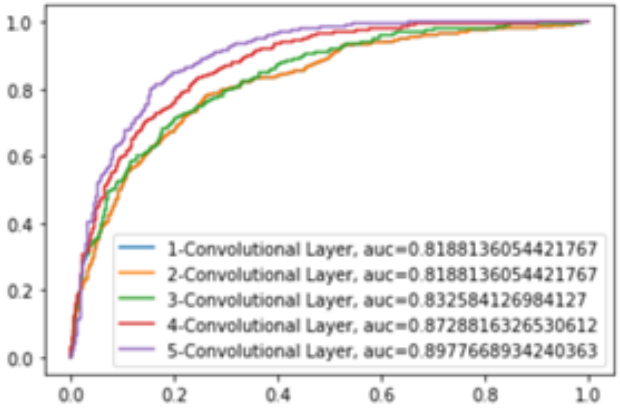

Figure 3: The AUC achieved for five CNN models

DISCUSSION

In the current study, a deep learning based method proposed method to solve the classification problem in OCT images. Validation results show that the proposed method effective in predicting the presence of DME in OCT images. This work employed convolutional neural network (CNN), giving the ability to assess in clinical practice and aid clinicians in real-time classification.

Patients with diabetes need a routine eye examination to provide earlier detection of referable eye disease and reduce complications. As the number of exams increase, the number of images will also increase, thus introduces a huge labor-intensive burden on the experts. Due to the challenging nature, such analyze images manually; learning-based solution to automate detection using deep learning technique could cope with challenges. As of now, deep learning appear promising and get into telemedicine rapidly, which in turn increase coverage and enable early detection of referable eye disease. Consequently, decrease costs of healthcare through earlier intervention of treatable disease rather than more costly interventions in advanced stages of disease. Additionally, efforts will grow towards developing datasets over time from the same patients to start infer patterns of disease progress through deep learning [19, 20]. Taking such solution one-step further and integrate it into the primary healthcare setting could reducing unnecessary referrals. Such technology would facilitate early diagnosis by enable ophthalmic self-monitoring and only patients with verified DME will refer to ophthalmologists. In this regard, further studies of development of DL tools that can more accurately detect DME in the eyes may be potentially reduce the overall referral burden [6, 7, 8, 16].

Even with promising and comparable results from previous research studies, there are multiple issues and limitations related to introducing deep learning methods in medical imaging practice in general. First, considering the image quality, amount of training image data, differences in imaging machines and protocols. All mentioned issues affect model ability to react with a new data and curtail to the success of the model. A more effective and efficient techniques therefore requires development. Second, difficulty in explaining the technical and logical bases behind deep learning techniques due to its black box nature. The possibility of such technique to fail due to unexpected condition is high. Third, we only managed to solve a binary classification problem between normal and abnormal (DME) images. Future researches could include more images from different OCT platforms and achieving expert-level performance. Moreover, classification of the outcomes of different DME patterns and severities could be studied. Therefore, a closer follow-up for patients with moderate or high DME urgently needed.

CONCLUSION

This work shows how Deep Learning can be effectively adopted in the health field, in particular medical imaging, to derive models that use patient image data to predict an outcome of interest. Deep Learning may be applied to the construction of models for the prediction of patients at high risk of DME, which – once evaluated– may be embedded within healthcare systems. Patients having high risk of DME can be predicted to set proactive interventions that reduce the negative impact and provides insightful implications for decision-making.

References

1. Abbas, Q., 2020. DME-Deep: A Computerize Tool for Detection of Diabetic Macular Edema Grading Based on Multilayer Deep Learning and Transfer Learning.
2. Alshaya, S., McCarren, A. and Al-Rasheed, A., 2019, December. Predicting No-show Medical Appointments Using Machine Learning. In International Conference on Computing (pp. 211-223). Springer, Cham
3. Chan, G.C., Muhammad, A., Shah, S.A., Tang, T.B., Lu, C.K. and Meriaudeau, F., 2017, September. Transfer learning for diabetic macular edema (DME) detection on optical coherence tomography (OCT) images. In *2017 IEEE international conference on signal and image processing applications (ICSIPA)* (pp. 493-496). IEEE.
4. De Fauw, J., Keane, P., Tomasev, N., Visentin, D., van den Driessche, G., Johnson, M., Hughes, C.O., Chu, C., Ledsam, J., Back, T. and Peto, T., 2016. Automated analysis of retinal imaging using machine learning techniques for computer vision. F1000Research, 5
5. Eladawi, N., Elmogy, M.M., Ghazal, M., Helmy, O., Aboelfetouh, A., Riad, A., Schaal, S. and El-Baz, A., 2018. Classification of retinal diseases based on OCT images. Front Biosci, 23, pp.247-64
6. Grewal, P.S., Oloumi, F., Rubin, U. and Tennant, M.T., 2018. Deep learning in ophthalmology: a review. *Canadian Journal of Ophthalmology*, *53*(4), pp.309-313.
7. Hsu, M.Y., Chiou, J.Y., Liu, J.T., Lee, C.M., Lee, Y.W., Chou, C.C., Lo, S.C., Kornelius, E., Yang, Y.S., Chang, S.Y. and Liu, Y.C., 2021. Deep Learning for Automated Diabetic Retinopathy Screening Fused With Heterogeneous Data From EHRs Can Lead to Earlier Referral Decisions. *Translational Vision Science & Technology*, *10*(9), pp.18-18.
8. Kermany, D.S., Goldbaum, M., Cai, W., Valentim, C.C., Liang, H., Baxter, S.L., McKeown, A., Yang, G., Wu, X., Yan, F. and Dong, J., 2018. Identifying medical diagnoses and treatable diseases by image-based deep learning. *Cell*, *172*(5), pp.1122-1131.
9. Kermany, Daniel; Zhang, Kang; Goldbaum, Michael (2018), "Labeled Optical Coherence Tomography (OCT) and Chest X-Ray Images for Classification", Mendeley Data, V2, doi: 10.17632/rscbjbr9sj.2. In Kaggle. [Online]. Available: https://data.mendeley.com/datasets/rscbjbr9sj/2
10. Kumar, A., Kim, J., Lyndon, D., Fulham, M. and Feng, D., 2016. An ensemble of fine-tuned convolutional neural networks for medical image classification. *IEEE journal of biomedical and health informatics*, *21*(1), pp.31-40.
11. Kwan, C.C. and Fawzi, A.A., 2019. Imaging and biomarkers in diabetic macular edema and diabetic retinopathy. *Current diabetes reports*, *19*(10), pp.1-10.
12. Lee, J.G., Jun, S., Cho, Y.W., Lee, H., Kim, G.B., Seo, J.B. and Kim, N., 2017
13. Li, F., Chen, H., Liu, Z., Zhang, X.D., Jiang, M.S., Wu, Z.Z. and Zhou, K.Q., 2019. Deep learning-based automated detection of retinal diseases using optical coherence tomography images. *Biomedical optics express*, *10*(12), pp.6204-6226.
14. Li, F., Wang, Y., Xu, T., Dong, L., Yan, L., Jiang, M., Zhang, X., Jiang, H., Wu, Z. and Zou, H., 2021. Deep learning-based automated detection for diabetic retinopathy and diabetic macular oedema in retinal fundus photographs. *Eye*, pp.1-9.
15. Li, Q., Cai, W., Wang, X., Zhou, Y., Feng, D.D. and Chen, M., 2014, December. Medical image classification with convolutional neural network. In *2014 13th international conference on control automation robotics & vision (ICARCV)* (pp. 844-848). IEEE.
16. Limwattanayingyong, J., Nganthavee, V., Seresirikachorn, K., Singalavanija, T., Soonthornworasiri, N., Ruamviboonsuk, V., Rao, C., Raman, R., Grzybowski, A., Schaekermann, M. and Peng, L.H., 2020. Longitudinal screening for diabetic retinopathy in a nationwide screening program: comparing deep learning and Human graders. *Journal of diabetes research*, *2020*.
17. Perdomo, O., Otálora, S., González, F.A., Meriaudeau, F. and Müller, H., 2018, April. Oct-net: A convolutional network for automatic classification of normal and diabetic macular edema using sd-oct volumes. In *2018 IEEE 15th international symposium on biomedical imaging (ISBI 2018)* (pp. 1423-1426). IEEE.

18. Pesapane, F., Codari, M. and Sardanelli, F., 2018. Artificial intelligence in medical imaging: threat or opportunity? Radiologists again at the forefront of innovation in medicine. European radiology experimental, 2(1), pp.1-10

19. Rahimy, E., 2018. Deep learning applications in ophthalmology. *Current opinion in ophthalmology*, *29*(3), pp.254-260.

20. Sahlsten, J., Jaskari, J., Kivinen, J., Turunen, L., Jaanio, E., Hietala, K. and Kaski, K., 2019. Deep learning fundus image analysis for diabetic retinopathy and macular edema grading. *Scientific reports*, *9*(1), pp.1-11.

21. Singh, A., Balaji, J.J., Rasheed, M.A., Jayakumar, V., Raman, R. and Lakshminarayanan, V., 2020. Quantitative and Qualitative Evaluation of Explainable Deep Learning Methods for Ophthalmic Diagnosis. arXiv preprint arXiv:2009.12648

22. Singh, R.K. and Gorantla, R., 2020. DMENet: diabetic macular edema diagnosis using hierarchical ensemble of CNNs. *Plos one*, *15*(2), p.e0220677.

23. Somasundaram, S.K. and Alli, P., 2017. A machine learning ensemble classifier for early prediction of diabetic retinopathy. Journal of Medical Systems, 41(12), pp.1-12.

24. Sreekanth, G.R., Latha, R.S., Suganthe, R.C., Sivakumar, S., Swathi, N., Sonasri, K. and Vaishnavi, S., 2021. Automated Detection and Classification of Diabetic Retinopathy and Diabetic Macular Edema in Retinal Fundus Images Using Deep Learning Approach. *NVEO-NATURAL VOLATILES & ESSENTIAL OILS Journal| NVEO*, pp.61-70.

25. Sultana, F., Sufian, A. and Dutta, P., 2018, November. Advancements in image classification using convolutional neural network. In *2018 Fourth International Conference on Research in Computational Intelligence and Communication Networks (ICRCICN)* (pp. 122-129). IEEE.

26. Tang, F., Wang, X., Ran, A.R., Chan, C.K., Ho, M., Yip, W., Young, A.L., Lok, J., Szeto, S., Chan, J. and Yip, F., 2021. A Multitask Deep-Learning system to classify diabetic macular edema for different optical coherence tomography devices: a multicenter analysis. *Diabetes Care*, *44*(9), pp.2078-2088.

27. Varadarajan, A.V., Bavishi, P., Ruamviboonsuk, P., Chotcomwongse, P., Venugopalan, S., Narayanaswamy, A., Cuadros, J., Kanai, K., Bresnick, G., Tadarati, M. and Silpa-Archa, S., 2020. Predicting optical coherence tomography-derived diabetic macular edema grades from fundus photographs using deep learning. *Nature communications*, *11*(1), pp.1-8.

28. Wang, W., Yang, Y., Wang, X., Wang, W. and Li, J., 2019. Development of convolutional neural network and its application in image classification: a survey. *Optical Engineering*, *58*(4), p.040901.

29. Wang, Z., Zhang, W., Sun, Y., Yao, M. and Yan, B., 2020. Detection of diabetic macular edema in optical coherence tomography image using an improved level set algorithm. *BioMed Research International*, *2020*.

30. Wu, Q., Zhang, B., Hu, Y., Liu, B., Cao, D., Yang, D., Peng, Q., Zhong, P., Zeng, X., Xiao, Y. and Li, C., 2021. Detection of morphologic patterns of diabetic macular edema using a deep learning approach based on optical coherence tomography images. Retina (Philadelphia, Pa.), 41(5), p.1110.

31. Yadav, S.S. and Jadhav, S.M., 2019. Deep convolutional neural network based medical image classification for disease diagnosis. *Journal of Big Data*, *6*(1), pp.1-18.

32. Yu, S., Jia, S. and Xu, C., 2017

33. Zhang, Q., Liu, Z., Li, J. and Liu, G., 2020. Identifying diabetic macular edema and other retinal diseases by optical coherence tomography image and multiscale deep learning. *Diabetes, Metabolic Syndrome and Obesity: Targets and Therapy*, *13*, p.4787.