



## Huge Gastric Trichobezoar Requiring Surgical Intervention in an Underweight Adolescent Female

**Nasib Al Shibli\***

ORCID: 0000-0003-3291-2656

Assistant Professor Aljouf University  
College of Medicine, Senior Registrar GS,  
Prince Mutaib bin Abdulaziz Hospital, Saudi Arabia

**Tariq Ijaz**

Consultant General Surgeon,  
Prince Mutaib bin Abdulaziz Hospital, Saudi Arabia

**Nayel Hamed Alsharari**

Consultant Gastroenterology,  
King AbdulAziz Specialisty Hospital, Saudi Arabia

**Alshammari Abdullaziz Mohammad**

GS Resident, Prince Mutaib Bin AbdulAziz Hospital

**Tamam Abdulrahman Aldaham**

Internship

**Mahmoud Abdou Yassin Ahmed**

Consultant General Surgeon,  
Prince Mutaib bin Abdulaziz Hospital, Saudi Arabia

### ABSTRACT

Trichotillomania was recognized as a psychological disorder characterized by the compulsive urge to pull out one's own hair, leading to noticeable hair loss. When ingested, this hair accumulated in the stomach and formed a trichobezoar — a rare and fascinating condition. Most cases of trichobezoar occurred in young female patients with underlying psychiatric disorders. We reported a case of an 18-year-old underweight female who presented with a two-month history of upper abdominal pain, intermittent vomiting, and epigastric discomfort. After two unsuccessful treatment attempts due to the size of the mass, surgical intervention was performed to remove the trichobezoar. Postoperatively, she was advised to receive intravenous antibiotics for one week due to the risk of infective endocarditis, which was justified by her history of congenital cardiac disease. Surgical removal remained the mainstay of treatment for trichobezoar. It was important to note that most patients had associated psychiatric or social issues.

---

\* Correspondence to: Dr Nasib Al Shibli. FACS, FRCS, MRCSEng. Arab Board. [nasib\\_kais@yahoo.com](mailto:nasib_kais@yahoo.com)

**Therefore, a multidisciplinary approach was considered essential to prevent recurrence.**

**Keywords:** Trichobezoar, surgery, endoscopy, laparotomy, trichotillomania.

## INTRODUCTION

A hard mass that forms in the gastrointestinal tract (GIT) as a result of ingested indigestible chemicals is called a bezoar. Based on their makeup, Bezoars are divided into four groups. (A) Indigestible material found in fruits and vegetables makes up phytobezoars; (B) Trichobezoars are primarily an accumulation of a patient's hair, though occasionally hair from toys, carpets, or animals is recovered; (C) Pharmacobezoars are made up of various undigested medications; and (D) Other bezoars are a diverse group that includes aggregates from a range of materials, including pieces of paper, gloves, shellac, styrofoam, cement, milk curd, and others. 1-2 Rapunzel syndrome is a rare type of trichobezoar. At the close of the eighteenth century, Baudomant published the first description of Trichobezoar. Other mental illnesses including anxiety and sadness may cause trichomoniasis. 3-4. The most frequent location for bezoar consolidation is the stomach. It might, however, travel distally to other GIT locations and clog the small intestine. There are various classifications for gastric bezoars. Trichobezoars, phytobezoars, pharmacobezoars, and other rare varieties are classified according to their composition. 5 About 40% of the described bezoar cases are of the most prevalent type, phytobezoar. Toxic plant filaments in the form of orange pits, seeds, thick natural products, roots, or takeoffs could be the bulk form. The other most frequently detailed kind is trichomoniar. 6-7 It is primarily made of hair, which is safe for peristalsis and digestion. As a result, it collects in the folds of the stomach and occasionally spreads outside of it into the digestive tract. 8The most frequent visitors are young women with mental health conditions who are under the age of thirty. Poor gastric motility, structural anomalies, ingestion of involved materials (such as fibers, hair, or drugs), and a number of concomitant diseases are some of the risk factors that predispose some people to bezoar development. Usually, gastroparesis, stomach operations, and other illnesses such hypothyroidism, amyloidosis, and scleroderma result in poor gastric motility. Pyloric stenosis and occlusion of the gastric outflow are the most prevalent anatomical anomalies 9-10. Additionally, insufficient fluid intake causes the GIT to produce less mucus, which lowers stomach motility. Bezoars typically show no symptoms. Symptoms start to appear when a bezoar gets bigger. In the uncommon event of a total intestinal blockage or rupture, a patient may exhibit immediate abdominal symptoms.11 We reported a case of a 18-year-old underweight female presented with a two-month history of upper abdominal pain, intermittent vomiting, and epigastric discomfort, after two unsuccessful attempts of treatments due to the size of mass, surgery was conducted to remove it and was advised to receive intravenous antibiotics for one week postoperatively due to the risk of infective endocarditis.

## CASE PRESENTATION

An underweight female patient, age 18, reported experiencing discomfort in the epigastric area, intermittent vomiting, and chronic upper abdomen pain for the past two months. Even though her symptoms were persistent, she had not sought medical help until her recent hospitalization. As part of her medical history, she was suspected of having psychosis.

## Medical History

She had two congenital heart defects in the past: an atrial septal defect (ASD), which had been successfully corrected with a transcatheter operation eight years earlier, and a ventricular septal defect (VSD) with a left-to-right shunt. To reduce the risk of infective endocarditis, a one-week course of intravenous antibiotics was advised following surgery based on the preoperative cardiology examination.

## Initial Presentation and Diagnostic Assessment

An upper gastrointestinal (GI) endoscopy revealed a sizable hair-based gastric foreign body during the patient's initial evaluation at a private medical facility. The patient was managed initially with IV fluids and analgesia and she was allowed to take sips of water. Diagnostic esophagogastroduodenoscopy was done and showed a large trichobezoar occupying the whole volume of the stomach up to the gastroesophageal junction, therefore the trial of endoscopic removal carried. After unsuccessful endoscopic attempts to remove the lump, she was referred to the emergency gastroenterology unit for additional testing. An oesophagogastroduodenoscopy (OGD) was tried later, but the hair mass was too large and entangled to be extracted. For additional management, the general surgery team was consulted intra-procedurally.

## Surgical Management

An upper midline mini-laparotomy was performed on the patient the same day of admission. A huge hair-filled trichobezoar that entirely filled the stomach and blocked the pylorus was discovered during surgery. The entire bulk was removed. After being irrigated with saline, the stomach was sealed. There was extensive washing of the peritoneal cavity. A nasogastric (NG) tube and surgical drain were inserted. A huge trichobezoar of more than 2.5kg was found and sensibly removed.

## Postoperative Course

Following surgery, a psychological consultation was requested. Over the next 48 hours, the patient's food was progressively increased as tolerated. On the third postoperative day, the abdominal drain was withdrawn, and the patient was sent home in stable condition with an appointment for an outpatient follow-up.

## DISCUSSION

In the middle of the 1800s, the first description of trichomonias was published. It is frequently observed in young females with trichotillomania, a kind of mental illness. Because bezoars take up space in the gastric lumen, they can result in a variety of gastrointestinal problems. Such a problem is frequently unknown to the patients and their families. Furthermore, diagnosing the condition is challenging and sometimes delayed due to its rarity and vague symptoms.<sup>12</sup>

Although they are extremely uncommon, gastric bezoars are typically found by chance in asymptomatic individuals who were being examined for other reasons. The size, location, and kind of undigested material all affect the clinical appearance. Abdominal distention, nausea, vomiting, dyspepsia, weight loss, halitosis, bloody stool, anemia, and upper gastrointestinal hemorrhage are the most typical signs of gastric bezoars. In our instance, the patient had a long

history of intermittent stomach pain that had been accompanied by nausea, vomiting, and constipation for over a month. 4-7

CT scans and ultrasounds are important diagnostic tools. For stomach bezoars, upper GI endoscopy is the most reliable and accurate diagnostic technique. It can also be used therapeutically for minor lumps. Imaging evidence is used to diagnose trichobezoars.<sup>2</sup> While CT-scan is more authentic in displaying bezoar characteristics and improving the likelihood of identifying gastrointestinal bezoars, ultrasound is capable of detecting the disorder. The definitive diagnosis is provided by endoscopy. If stomach bezoar is suspected, endoscopy should be the first diagnostic procedure performed because it is the gold standard.<sup>3</sup>

Trichobezoars range in size from tiny (2 × 2 cm in diameter) to enormous (30 × 15 × 10 cm). 8–11 Trichobezoars are typically observed to be 5.5 cm in size (mean, 3-10 cm). 12, 13 In our instance, the trichobezoar was roughly 17 × 13 × 11 cm in size, placing it in the category of enormous trichobezoars.<sup>6</sup>

The size, position, and consistency of a trichobezoar determine how it should be treated. Depending on the size and density of the hair, endoscopy typically fails to remove the mass of the hair. Surgery is still the recommended course of treatment since it allows for a full examination of the gastrointestinal tract and has a low likelihood of complications and higher success rates.

Depending on the facility and experience, either laparotomy or laparoscopy is the preferred management approach. Using a modified needle knife and mono-polar coagulation current, a big foreign body is broken up. The density, size, and hardness of the bezoars made this challenging in the majority of the case reports. Among them, conventional laparotomy is the method of choice for the removal of a trichobezoar. Laparoscopy techniques have also been described in the recent literature as a novel method for removing small to moderate sized bezoars. In cases with large trichobezoars, laparoscopic management is difficult due to the fact that the longer duration of laparoscopic surgery will result in a higher risk of migration of the hairball toward ileum and specifically the risk of spilling contaminated hair fragments into the abdominal cavity.<sup>5-6</sup>

The second objective of therapy is to avoid recurrence by addressing and identifying the risk factors following bezoar excision. A bezoar's recurrence rate could be 13.5%<sup>5</sup>. A gastroparesis diet consisting of small, frequent meals, lower total fiber, and a focus on liquids is likely to be beneficial for patients with comorbidities related to stomach dysmotility. For people who have trichobezoars, a mental health evaluation is necessary. Additionally, long-term treatment along with psychiatric consultation is necessary to enhance the patient's quality of life and prevent relapse.<sup>12</sup>

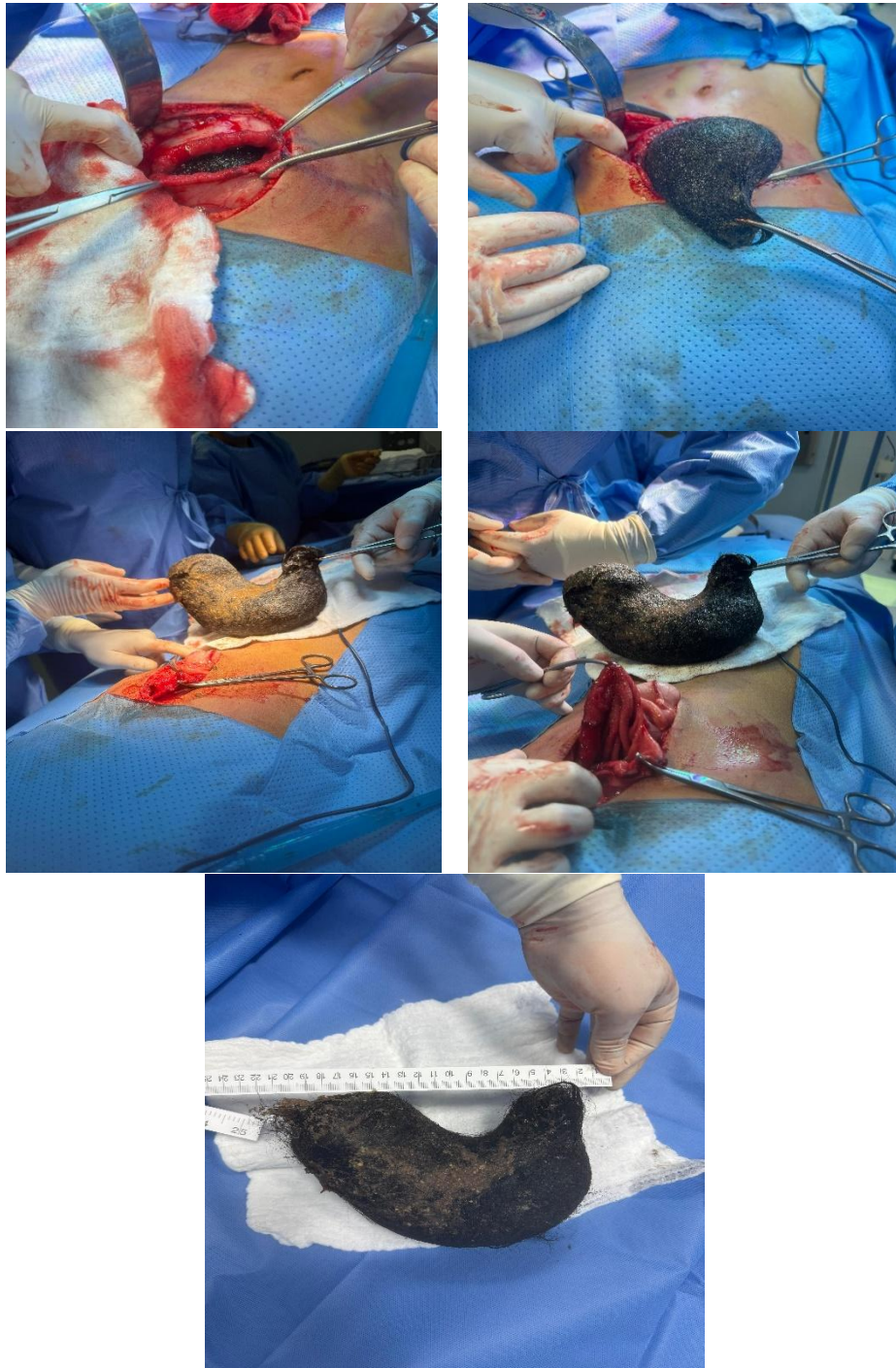
## CONCLUSION

Although gastrointestinal tract trichomoniasis is an uncommon ailment, it can be quite dangerous. In addition to the subtle clinical signs that may aid in early clinical inquiry and diagnosis, doctors must be aware of the risk factors that contribute to the development of trichobezoars. When a young female patient has a movable epigastric mass, trichomoniasis

should be evaluated as a differential diagnosis and requires a high index of suspicion for diagnosis. Making a diagnosis is simple. Surgical removal is always necessary for management. It should be noted that the vast majority of these patients suffer from a social or mental illness. A multidisciplinary strategy is necessary to stop the issue from happening again.

## References

1. Khan S, Jiang K, Zhu L-P, et al. Upper gastrointestinal manifestation of bezoars and the etiological factors: a literature review. *Gastroenterol Res Pract*. 2019; 2019: 5698532.
2. Delimpaltadaki DG, Gkionis IG, Flamourakis ME, et al. A rare giant gastric trichobezoar in a young female patient: Case report and review of the literature. *Clin Case Rep*. 2021; 9:e05152. doi:10.1002/ccr3.5152
3. Malpani A, Ramani SK, Wolverson MK. Role of sonography in trichobezoars. *J Ultrasound Med* 1988 Dec;7(12):661-3
4. Mohammed AA, Arif SH, Qadir RH, Salih AM, Kakamad FH. Surgical extraction of a giant trichobezoar: A rare presentation. *Int J Case Rep Images* 2018;9:100929Z01AM2018
5. Robert Wyllie JS. *pediatric Gastrointestinal and Liver Disease (Sixth Edition)*, 2021. 2.
6. Palchaudhuri S. Bezoars: Recognizing and Managing These Stubborn, Sometimes Hairy, Roadblocks of the Gastrointestinal Tract. *Pract Gastroenterol* 2021 Mar.
7. Samiullah Khan, "Upper Gastrointestinal Manifestation of Bezoars and the Etiological Factors: A Literature Review," pubmed, 15 July
8. Asma Darwish Juma Al Kahlali<sup>1</sup>, Salma Amur Abdullah Al Khanjari and Ibrahim Al Alawi Gastric Trichobezoar: Case Report and Literature Review. *Oman Med J*. 2025;40(1):26. doi:10.5001/omj.2027.26
9. Aslanabadi, Saeid & Badebarin, Davoud & Parsay, Sina & Jamshidi, Masoud & Farhadi, Ebrahim & Ladan, Amirhossein & Ladan, Amir Hossein. (2019). A Case of Giant Gastric Trichobezoar Case Report. *Iranian Journal of Pediatric Surgery*. 5. 98-101. 10.22037/irjps.v5i2.23729.
10. Jha, Ashish & Mishra, Manishkumar & Kumar, Rakesh & Chaudhary, Madhur & Purkayastha, Shubham & Jha, Praveen & Raza, Nazis. (2018). Giant Gastroduodenal Trichobezoar: An Endoscopic Surprise. *Journal of Digestive Endoscopy*. 9. 131. 10.4103/jde.JDE\_2\_18.
11. Iwamuro M, Okada H, Matsueda K, et al. Review of the diagnosis and management of gastrointestinal bezoars. *World J Gastrointest Endosc* 2015;7:336-45.
12. Mihai C, Mihai B, Drug V, et al. Gastric bezoars-diagnostic and therapeutic challenges. *J Gastrointest Liver Dis*. 2013; 224



**Figures 1A to 1 E: A: Laparotomy, B: Removal of bezoar, C: Bezoar D: Closure of stomach and abdominal wall, E: Measurement of Bezoar**