ISSN 2055-0286
Advances in Social Sciences Research Journal; Vol. 13 No. 11 (2026) (453-475)
https://doi.org/10.14738/assrj.1311.12735

Regenerative Endodontic Therapies

Peter E. Murray[1]* & Franklin Garcia-Godoy[2]

1. 490 Post St, Ste 500 PMB 2045, San Francisco, CA 94102, USA
2. University of Tennessee Health Science Center, College of Dentistry, Memphis, TN 38103, USA

Abstract: Contemporary endodontics is undergoing a fundamental transition from the removal and replacement of diseased pulp toward biologically based strategies that prioritize tissue preservation, continued root development, and ultimately regeneration of the pulp-dentin complex. Although conventional root canal therapy remains an effective and predictable treatment, it preserves the tooth without restoring the vascular, neural, immunological, and dentinogenic functions of native pulp. This limitation is particularly consequential in immature permanent teeth, where premature pulpal necrosis can arrest root development, leaving thin dentinal walls, short roots, and open apices that compromise long-term structural integrity. Advances in pulpal biology and tissue engineering have expanded therapeutic possibilities along a continuum encompassing vital pulp therapy, apexogenesis, apexification, regenerative endodontic procedures, and emerging strategies for engineered pulp regeneration. Vital pulp therapies, including indirect pulp treatment, direct pulp capping, and partial or complete pulpotomy, aim to preserve healthy or functionally recoverable tissue, thereby maintaining essential biological functions and, in immature teeth, permitting continued physiological root maturation through apexogenesis. When pulpal necrosis occurs, apexification provides an established means of achieving apical closure but does not predictably restore root development. Regenerative endodontic procedures seek to overcome this limitation by promoting endogenous cell recruitment, scaffold-supported tissue formation, and biological signaling within disinfected root canals, potentially enabling revitalization and continued root maturation. However, clinical healing and intracanal tissue formation do not necessarily constitute true pulp regeneration, which requires restoration of the characteristic architecture and biological functions of the native pulp-dentin complex. Emerging approaches involving dental stem and progenitor cells, biomimetic scaffolds, controlled molecular signaling, and vascular and neural tissue engineering offer promising opportunities for more complete biological reconstruction. Dental stem-cell banking may support future cell-based applications, although its clinical utility remains unproven. This review critically examines the biological foundations, clinical applications, therapeutic limitations, and translational prospects of established and emerging endodontic strategies, emphasizing a biologically individualized treatment continuum in which preservation of native pulp takes precedence whenever feasible, repair and revitalization are pursued when tissue is lost, and true regeneration remains the ultimate objective of advanced tissue engineering.

Keywords: regenerative endodontics, vital pulp therapy, pulp capping, pulpotomy, apexogenesis, apexification, revascularization, revitalization, dental pulp stem cells, tissue engineering, stem-cell banking

INTRODUCTION

Interest in regenerative endodontic therapies (RET) is growing across dentistry, reflecting a shift from conventional tissue removal and replacement toward biological preservation, repair, and regeneration. This interest is substantial, with 96% of dentists expressing a desire

to incorporate additional RETs into clinical practice to improve the restoration or replacement of diseased, injured, or lost tissues.[1]

Historically, endodontic treatment of irreversibly inflamed or necrotic pulp has focused on removing diseased tissue, disinfecting the root canal system, and obturating the resulting space to prevent reinfection.[2] This approach remains indispensable to contemporary dentistry, allowing teeth affected by pulpal and periapical disease to remain functional for decades, with a reported success rate of 68% over follow-up periods extending to 37 years.[3] Nevertheless, conventional root canal therapy achieves tooth preservation without restoring the vascular, neural, immunological, and dentinogenic functions of the native pulp-dentin complex.[4] This distinction between maintaining tooth function and restoring biological function provides a fundamental rationale for using RETs.

Advances in pulpal biology have challenged the assumption that clinically significant inflammation necessarily requires complete pulp removal.[5] Evidence that inflamed pulp may retain substantial healing and reparative potential, particularly when microbial contamination is controlled, has expanded the clinical relevance of vital pulp therapy.[6] Indirect pulp treatment, direct pulp capping, partial pulpotomy, and complete pulpotomy now represent a continuum of increasingly extensive interventions intended to preserve healthy or functionally recoverable tissue while achieving predictable disease control.[7,8]

Pulp preservation is particularly consequential in immature permanent teeth, where continued root development depends on coordinated activity among the pulp, odontoblasts, apical papilla, Hertwig's epithelial root sheath, and surrounding apical tissues.[9] Maintaining these tissues permits continued root elongation, dentinal wall thickening, and apical maturation. Conversely, premature pulpal necrosis can arrest root development, leaving short roots, thin dentinal walls, and open apices that complicate treatment and increase susceptibility to fracture and tooth loss.[2,10]

Apexification has traditionally addressed these challenges by establishing an apical barrier through prolonged calcium hydroxide treatment or, more recently, hydraulic calcium silicate materials [8]. Although effective in facilitating obturation and resolving apical disease, apexification does not predictably restore physiological root development. RETs seek to overcome this limitation by creating conditions favorable to endogenous progenitor-cell recruitment, intracanal tissue formation, and potentially continued root maturation.[5]

Beyond these clinically applied procedures, advances in stem-cell biology and tissue engineering have introduced the prospect of reconstructing the pulp-dentin complex itself. Dental pulp stem cells (DPSCs), stem cells from human exfoliated deciduous teeth, stem cells from the apical papilla, biomaterial scaffolds, growth factors, extracellular vesicles, and strategies promoting vascularization and innervation are being investigated for their potential to restore native tissue architecture and function.[5,6] The collection and banking of DPSCs has emerged alongside these developments as a potential source of autologous cells for future regenerative applications.[11,12] However, the clinical translation of these technologies remains dependent on further biological, technological, regulatory, and clinical validation. Collectively, these advances establish a therapeutic continuum extending from preservation of viable pulp through repair and revitalization to the potential regeneration of the pulp-dentin complex. Importantly, clinical healing, revascularization, revitalization, repair, and true regeneration represent distinct biological outcomes and should not be used interchangeably.[7,8]

This review examines established and emerging RETs within an integrated biological and clinical framework, evaluates their therapeutic objectives and limitations, clarifies the terminology used to characterize their outcomes, and identifies the scientific and translational challenges that must be overcome to achieve predictable functional pulp regeneration.

BIOLOGICAL RATIONALE FOR PRESERVING THE PULP-DENTIN COMPLEX

The dental pulp and dentin constitute an integrated biological system rather than two functionally independent tissues. Odontoblasts form a specialized cellular layer at the periphery of the pulp and extend cytoplasmic processes into the dentinal tubules, creating a direct structural and functional interface between the pulp and the surrounding mineralized dentin.[13] Through this relationship, changes within dentin can influence pulpal responses, while the biological status of the pulp determines the capacity of the tooth to maintain dentin homeostasis and respond to injury through further mineralized tissue formation.[14] Preservation of the pulp-dentin complex therefore maintains a dynamic, responsive tissue system rather than simply retaining vital tissue within the root canal space.

The response of this complex to injury is influenced by the nature, severity, duration, and microbial burden of the insult.[15] When injury is limited and primary odontoblasts survive, these cells can respond by increasing the deposition of reactionary dentin.[15] With more severe injury, local odontoblasts may be destroyed; however, if the underlying pulp remains sufficiently viable, resident progenitor cells can be recruited and differentiate into odontoblast-like cells that deposit reparative dentin or other mineralized tissue.[16] Thus, pulpal inflammation and odontoblast injury do not necessarily signify irreversible loss of reparative potential. The ability of surviving pulp tissue to resolve inflammation, recruit progenitor cells, and generate a mineralized barrier provides an important biological foundation for vital pulp therapy.[16] The value of preserving the pulp extends beyond its capacity to form dentin. The pulp is a vascularized, innervated, and immunologically active connective tissue that performs multiple functions that conventional root canal filling materials cannot reproduce. Its vascular network delivers oxygen and nutrients, removes metabolic waste, and supports inflammatory, immune, and reparative processes.[17] Neural components mediate nociception and participate in neurovascular regulation, while resident and recruited immune cells provide surveillance and defense against microbial invasion.[18] Pulpal progenitor cells can migrate toward sites of injury and contribute to mineralized tissue repair,[19] while odontoblasts preserve the biological interface between pulp and dentin and contribute to dentin formation throughout the life of the tooth.[13] Maintaining viable pulp therefore preserves the tooth's capacity for biological defense, sensation, repair, and continued dentin formation rather than merely avoiding conventional root canal treatment.

CONVENTIONAL ENDODONTIC THERAPY AND THE TRANSITION TOWARD BIOLOGICAL PRESERVATION

Conventional root canal therapy remains an essential and highly effective treatment when the pulp is necrotic or when preservation of viable pulp tissue is neither biologically appropriate nor clinically predictable.[7] Its principal objective is control of intracanal infection and prevention of reinfection.[3] Diseased or necrotic pulp tissue is removed, the

root canal system is mechanically prepared and chemically disinfected, and the resulting space is obturated and coronally sealed to limit microbial re-entry. When appropriately performed, this approach can promote resolution of apical periodontitis and permit long-term retention and function of the affected tooth.[3]

The clinical effectiveness of conventional root canal therapy does not, however, eliminate its biological limitations.[5] Instrumentation, disinfection, and obturation control disease but do not restore the native pulp-dentin complex. Following treatment, the root canal space no longer contains the vascular, neural, immune, progenitor-cell, and odontoblastic components responsible for normal pulp homeostasis, defense, sensation, repair, and continued dentin formation.[5]

In addition, endodontic access and canal instrumentation require removal of tooth structure and may contribute to mechanical weakening. The fracture susceptibility of an endodontically treated tooth, however, reflects multiple factors, including the extent of preexisting caries or structural loss, access design, removal of radicular dentin, and the quality and design of the definitive restoration.[21] Thus, the biological and structural consequences of treatment should be considered alongside its well-established capacity to control infection and preserve the tooth.

Recognition of these limitations, together with advances in understanding pulpal inflammation and healing, has contributed to a more biologically conservative approach when viable pulp tissue can reasonably be preserved.[22] The central clinical question is increasingly not simply whether a patient presents with symptoms traditionally associated with irreversible pulpitis, but whether sufficient healthy or functionally recoverable pulp remains after removal of caries, infected dentin, and, when necessary, severely inflamed coronal pulp tissue.[7,8] This distinction is important because clinical symptoms and conventional diagnostic categories do not necessarily correspond precisely to the histopathological condition of the pulp.[5] Even teeth presenting with severe spontaneous or lingering pain may exhibit pronounced inflammation in the coronal pulp while deeper radicular tissue remains viable and retains the capacity for healing.[23]

VITAL PULP THERAPY: FROM PULP CAPPING TO PULPOTOMY

Vital pulp therapy encompasses a spectrum of biologically based procedures that differ principally in the extent of dentin and pulp tissue removed before the remaining pulp is protected.[7,8] Despite these procedural differences, the underlying therapeutic objective is consistent: to control microbial contamination, remove tissue that is irreversibly damaged when necessary, and preserve the greatest possible amount of healthy or functionally recoverable pulp. Selection among these procedures should therefore reflect the extent of disease, degree of pulpal exposure and contamination, condition of the remaining tissue, and likelihood that a durable biological and coronal seal can be achieved. Indirect pulp treatment represents the most conservative approach and is appropriate when deep caries approaches the dental pulp, but direct exposure can potentially be avoided.[8] Contemporary caries management recognizes that complete removal of all softened or discolored dentin, particularly near the pulp, may unnecessarily increase the risk of pulpal exposure and injury.[15]

Selective caries removal seeks instead to remove sufficient diseased tissue to permit placement of a durable restoration while retaining dentin near the pulp when its removal would jeopardize pulpal vitality. Once the lesion is effectively sealed from the oral environment, the reduction in available nutrients and microbial activity can arrest or substantially suppress the carious process while allowing the pulp-dentin complex to mount a defensive and reparative response.[8] This approach illustrates a central principle of biologically based dentistry: predictable disease control does not necessarily require maximal tissue removal.

When direct pulp exposure occurs, direct pulp capping may be appropriate in carefully selected cases.[8] A biocompatible material is placed directly over the exposed pulp to protect the tissue, promote healing, and facilitate formation of a mineralized barrier.[8] CH historically served as the principal pulp-capping material because of its high alkalinity, antimicrobial effects, and ability to stimulate hard-tissue formation. However, limitations including solubility, degradation over time, and inconsistent barrier formation contributed to the development and adoption of hydraulic calcium silicate materials, including mineral trioxide aggregate and related bioceramics.[8] Their favorable biocompatibility, sealing properties, and bioactivity have strengthened the biological foundation and expanded the clinical potential of contemporary vital pulp therapy.[16]

The predictability of direct pulp capping nevertheless depends substantially on the biological condition of the underlying pulp and the circumstances surrounding the exposure.[8] A small, recently created, minimally contaminated exposure differs biologically from a carious exposure associated with a greater microbial burden and more extensive pulpal inflammation.[24] When inflammation or tissue damage is believed to extend beyond the immediate exposure site, partial pulpotomy provides a more conservative alternative to complete pulp removal. A limited portion of the superficial coronal pulp is removed to reach tissue judged clinically to be healthier and more capable of healing [8]. The appearance of the remaining pulp and the ability to achieve hemostasis provide useful, although imperfect, clinical indicators of tissue status.[25] Once adequate hemostasis is obtained, a bioactive material is placed over the residual pulp and covered by a well-sealed definitive restoration to minimize subsequent microbial contamination.[25]

Complete pulpotomy extends the same biological principle by removing the entire coronal pulp while preserving viable radicular pulp tissue.[8] Historically, pulpotomy was associated primarily with immature permanent teeth, in which maintenance of pulp vitality permits continued root development. Contemporary evidence, however, has expanded interest in complete pulpotomy as a definitive treatment for selected mature permanent teeth, including some teeth presenting with signs and symptoms traditionally associated with irreversible pulpitis.[8] This development reflects growing recognition that clinical symptoms do not necessarily indicate irreversible inflammation or necrosis throughout the entire pulp.[5] If severely inflamed coronal tissue can be removed, microbial contamination adequately controlled, hemostasis achieved, and the remaining radicular pulp protected by a biocompatible material and durable coronal seal, preservation of functional radicular pulp may remain biologically and clinically achievable.[17]

Indirect pulp treatment, direct pulp capping, partial pulpotomy, and complete pulpotomy can therefore be viewed as successive points along a therapeutic continuum rather than as isolated procedures.[7,8] Progression along this continuum involves increasingly

extensive removal of compromised tissue while maintaining the same fundamental objective: preservation of the maximum amount of pulp that retains meaningful biological and reparative potential. The appropriate intervention is consequently not determined solely by traditional diagnostic terminology or the presence of pulpal exposure, but by an integrated assessment of microbial contamination, tissue injury, pulpal viability, capacity for hemostasis and healing, and the ability to establish a durable coronal seal. In this framework, vital pulp therapy represents a biologically guided strategy for matching the extent of intervention to the extent of disease while preserving as much of the native pulp-dentin complex as predictably possible.

APEXOGENESIS AND THE BIOLOGICAL IMPORTANCE OF CONTINUED ROOT DEVELOPMENT

Preservation of pulp vitality assumes particular importance in immature permanent teeth because continued root development depends on the survival and coordinated activity of viable pulpal, radicular, and apical tissues.[8] Apexogenesis refers to the continued physiological development and maturation of the root and apex in a tooth with vital pulp tissue.[8] It is therefore more accurately understood as a biological outcome of successful pulp preservation than as a distinct operative procedure. Vital pulp therapies, including pulp capping and pulpotomy, provide the clinical means by which the tissues necessary for apexogenesis may be preserved.

When healthy or functionally recoverable radicular pulp is maintained in an immature permanent tooth, the biological processes responsible for root development can continue.[8] Continued odontogenic activity permits further deposition of radicular dentin, resulting in increased root length, progressive thickening of dentinal walls, and gradual narrowing and eventual maturation of the apical opening.[5] These changes are clinically important because they improve the structural characteristics of the developing tooth. A longer root with thicker dentinal walls provides greater resistance to functional stresses and fracture than the short, thin-walled root that may result when development is prematurely arrested.[5] Thus, preservation of pulp vitality in an immature tooth serves not only to maintain living tissue but also to protect the developmental potential and long-term structural prognosis of the tooth.

The distinction between apexogenesis and apexification is therefore fundamental.[8] Although both concepts concern immature permanent teeth with incomplete root formation, they arise from fundamentally different biological circumstances. Apexogenesis depends on the preservation of vital pulp and the continuation of physiological root development. Apexification, by contrast, is undertaken when pulpal necrosis has interrupted normal root maturation and the developmental potential of the pulp has been lost.[8] Its objective is not to restore physiological root development, but to establish an apical barrier or endpoint that permits effective sealing of a root canal with an open apex.

APEXIFICATION AND ITS BIOLOGICAL LIMITATIONS

Before the introduction of RETs, apexification was the principal treatment for immature permanent teeth with necrotic pulps and open apices.[8] Because pulpal necrosis interrupts the physiological processes responsible for continued root development, treatment

traditionally focused on creating an apical barrier that would permit effective obturation of the otherwise open root canal system. Conventional apexification relied on repeated placement of calcium hydroxide (CA) over an extended period to induce formation of a mineralized barrier at or near the root apex.[8] Although this approach could achieve apical closure and facilitate subsequent obturation, treatment often required multiple appointments over several months and prolonged management of an already structurally compromised immature tooth.[5]

The introduction of mineral trioxide aggregate (MTA) and related hydraulic calcium silicate materials (HCSMs) substantially changed the clinical approach to apexification.[8] Rather than relying on biological formation of an apical barrier over an extended period, these materials allow the clinician to create an artificial apical plug that provides an immediate barrier against which the remainder of the canal can be obturated.[8] This approach shortens treatment time, reduces dependence on patient compliance with multiple appointments, and provides a predictable means of establishing an apical endpoint in teeth with open apices. Consequently, HCSM apical barriers have become an important strategy for managing necrotic immature permanent teeth.

Despite these clinical advantages, apexification has an important biological limitation: successful apical closure does not equate with restoration of physiological root development.[8] Whether an apical barrier is induced biologically with CA or created artificially with a HCSM, the procedure primarily addresses the problem of an open apex. It does not predictably restore the pulpal, odontogenic, and apical developmental processes lost following pulpal necrosis. Consequently, the root may remain relatively short, dentinal walls may remain thin, and the structural deficiencies associated with premature arrest of root development may persist despite successful disinfection and apical closure.[5,8] The tooth may therefore be clinically treatable yet remain mechanically vulnerable.

REGENERATIVE ENDODONTICS AND THE CONCEPT OF TISSUE ENGINEERING

RETs applies the principles of developmental biology, stem-cell biology, and tissue engineering to the treatment of diseased or damaged pulp-dentin tissues [5]. Unlike conventional endodontic therapy, which primarily seeks to eliminate infection and replace the contents of the root canal with an inert filling material, RET strategies attempt to establish a biological environment capable of supporting the formation of living tissue and, ideally, restoration of functions associated with the native pulp-dentin complex.[5] In its classical form, tissue engineering depends on the coordinated interaction of three principal components: responsive stem or progenitor cells, a three-dimensional scaffold, and biological signaling molecules that guide cell behavior and tissue organization.[27,28] Regenerative activity must occur within an environment in which microbial contamination is adequately controlled, vascular support can be established, and subsequent reinfection is prevented.[27,28]

The cellular component may be provided either through recruitment of endogenous cells from surrounding tissues or through transplantation of exogenous cells expanded or manipulated outside the tooth.[19] Contemporary clinical RETs rely predominantly on endogenous cell homing, thereby avoiding the additional complexity associated with cell isolation, expansion, storage, and transplantation.[19] This approach is particularly applicable to immature permanent teeth because the open apex provides communication between the

disinfected root canal and periapical tissues containing potentially responsive progenitor populations. Of particular importance are "stem cells from the apical papilla," which possess proliferative and odontogenic potential and may contribute to continued root development and intracanal tissue formation.[28] Clinically induced bleeding from the periapical tissues into the disinfected canal can introduce progenitor cells together with platelets, fibrin, growth factors, and other signaling molecules.[6]

The scaffold provides the three-dimensional microenvironment within which recruited cells can attach, migrate, proliferate, differentiate, and produce extracellular matrix.[26] In conventional RETs, the intracanal blood clot serves as an endogenous scaffold while also providing platelets and signaling molecules that may support tissue formation. However, the composition, volume, and biological properties of a blood clot are inherently variable. Consequently, platelet-rich plasma, platelet-rich fibrin, collagen matrices, hydrogels, and other natural or synthetic biomaterials have been investigated as alternative or supplementary scaffolds designed to provide a more controlled environment for tissue organization and regeneration.[6]

The third major component comprises "biological signaling molecules" that regulate cellular recruitment, survival, proliferation, angiogenesis, differentiation, and extracellular matrix production.[25] Importantly, dentin is not merely a structural substrate but also a reservoir of bioactive molecules incorporated into the dentinal matrix during tooth development. Appropriate chemical conditioning of canal walls can release or expose some of these sequestered growth factors, potentially enhancing cell recruitment, differentiation, and tissue repair.[25,28] The biological effects of RET protocols therefore depend not only on the introduction of cells and a scaffold but also on interactions between those cells and signaling molecules derived from blood, dentin, periapical tissues, and any exogenously applied biomaterials.

These three components cannot function effectively in isolation. Microbial control is a prerequisite for regeneration, because persistent infection and inflammation can compromise cell survival, disrupt signaling pathways, and prevent organization of newly forming tissue.[5] At the same time, disinfection must be sufficiently biologically conservative to avoid excessive damage to progenitor cells, dentin-derived signaling molecules, and the microenvironment required for healing. Regenerative endodontics therefore requires a balance between antimicrobial effectiveness and preservation of regenerative potential.

REVASCULARIZATION, REVITALIZATION, AND REGENERATION

The terminology used to describe RETs has evolved as understanding of their biological outcomes has advanced.[5] Early terminology sometimes implied specific biological effects that subsequent histological evidence could not consistently confirm.[8] The term revascularization was initially adopted because these procedures appeared to permit reestablishment of a vascular supply within root canals that had previously contained necrotic tissue.[8] Revascularization is biologically important because newly formed tissue requires an adequate blood supply for delivery of oxygen and nutrients, removal of metabolic waste, and long-term survival.[6] Nevertheless, the presence of blood vessels within the canal demonstrates vascular ingrowth, not restoration of the native dental pulp. Revascularization should therefore be regarded as an important component of tissue survival rather than as evidence of pulp regeneration itself.

The term revitalization more broadly describes the establishment of living tissue within a canal that previously contained necrotic tissue.[5] This terminology avoids assuming that the newly formed tissue is histologically or functionally equivalent to the original pulp.[6] Importantly, recovery of tissue vitality, including vascularization or a positive response to sensibility testing, does not by itself demonstrate regeneration of the pulp-dentin complex.[5] Histological examination of teeth treated with RETs has shown that the canal space may become occupied by fibrous connective tissue, cementum-like tissue, bone-like tissue, periodontal ligament-like tissue, or combinations of these tissues rather than by a normal pulp containing the characteristic cellular organization and peripheral odontoblastic layer of the native tissue.[29] Thus, revitalization describes the return of living tissue to the canal without defining its precise histological identity.

This distinction leads to the broader concepts of repair and regeneration. Repair restores tissue continuity and contributes to healing but does so through formation of tissue that may differ structurally and functionally from the tissue that was lost.[29] Within the root canal, such tissue may nevertheless provide substantial clinical benefit by contributing to resolution of apical disease, deposition of mineralized tissue, thickening of dentinal walls, and continued root maturation.[7]

Regeneration, in contrast, implies restoration of tissue that reproduces the essential architecture, cellular organization, and biological functions of the original pulp-dentin complex.[5] True pulp regeneration would therefore require more than the presence of vascularized connective tissue.[29] It would ideally include an appropriately organized vascular and neural network, relevant immune and progenitor-cell populations, and a functional odontoblastic layer capable of interacting with dentin and contributing to dentinogenesis.[5]

Accordingly, the term RET is useful clinically because it describes a biologically based therapeutic strategy without requiring proof that complete histological regeneration has occurred.[5] The term should not, however, be interpreted as evidence that the resulting intracanal tissue necessarily represents regenerated dental pulp.[29] A procedure may appropriately be classified as regenerative in its therapeutic intent and biological approach while its actual tissue-level outcome consists predominantly of revascularization, revitalization, or repair.[7]

The distinction between these terms is particularly important when interpreting clinical outcomes. Resolution of signs and symptoms and healing of apical periodontitis demonstrate clinical success, while increases in root length, dentinal wall thickness, or apical maturation demonstrate continued developmental or reparative activity.[5] Evidence of intracanal blood flow or responsiveness to sensibility testing may support revitalization, but none of these findings alone establishes true pulp regeneration.[29] The demonstration of regeneration requires evidence that the newly formed tissue reproduces important structural and functional characteristics of the native pulp-dentin complex.

CLINICAL BIOLOGY OF REGENERATIVE ENDODONTIC PROCEDURES

RET is particularly relevant to immature permanent teeth with pulpal necrosis because their anatomy presents both a significant therapeutic challenge and a favorable biological opportunity.[5] Premature loss of pulp vitality arrests normal root development, often leaving

a short root with thin dentinal walls and an open apex.[2] These structural characteristics make extensive mechanical instrumentation undesirable and can complicate conventional obturation.[5] At the same time, the wide apical opening provides direct communication with vascularized periapical tissues and may facilitate the migration of blood vessels, signaling molecules, and endogenous progenitor cells into the disinfected canal.[14] The same anatomy that makes conventional treatment difficult may therefore provide conditions favorable for biologically based tissue formation.

Microbial control is the essential first requirement for regenerative treatment.[5] A necrotic root canal contains microorganisms, microbial products, and necrotic tissue capable of sustaining inflammation and impairing the survival, recruitment, and differentiation of cells necessary for tissue formation.[5] Unlike conventional root canal therapy, however, RET must achieve adequate disinfection while preserving an intracanal environment compatible with subsequent biological activity.[27,28]

The main problem is that excessive mechanical instrumentation may further weaken already thin dentinal walls, while overly cytotoxic irrigants or intracanal medicaments may adversely affect surviving progenitor cells and alter dentin-derived bioactive molecules.[28] RETs therefore requires a deliberate balance between sufficient antimicrobial activity and preservation of the biological conditions necessary for healing and tissue development.[25]

Once the microbial burden has been sufficiently reduced, the canal must provide an environment capable of supporting cell recruitment, adherence, and tissue ingrowth.[28] In conventional regenerative protocols, deliberate irritation of the periapical tissues is used to induce bleeding through the open apex and into the disinfected canal.[5] The resulting blood clot performs several biological functions.[5] It provides a three-dimensional fibrin scaffold for cellular attachment and migration while introducing platelets, signaling molecules, and potentially responsive cells from the periapical tissues.[5] Stem cells from the apical papilla are of particular interest because of their proximity to the developing root apex and their substantial proliferative and odontogenic potential.[12] Their recruitment into the canal may contribute to intracanal tissue formation and continued development of the immature root.

Following establishment of the intracanal scaffold,[26] the newly created biological environment must be protected from coronal reinfection. A biocompatible material is placed over the scaffold, followed by a durable coronal restoration capable of limiting microbial penetration from the oral environment. The coronal seal is therefore not merely a restorative consideration but an integral component of the regenerative strategy. Even successful disinfection and tissue ingrowth may be compromised if microorganisms subsequently regain access to the canal.[5]

Clinical outcomes are correspondingly multidimensional and should be interpreted hierarchically.[7] The primary objective is elimination of clinical signs and symptoms and healing of apical disease, reflecting effective control of infection.[7] A secondary and particularly valuable objective in immature teeth is continued root development, including increased root length, thickening of dentinal walls, and progressive apical maturation, because these changes may improve the structural prognosis of the tooth.[5] Additional evidence of biological activity, such as restoration of responsiveness to pulp sensibility testing, may suggest the presence of viable and potentially innervated intracanal tissue.[2]

DENTAL STEM CELLS AND THE TRANSITION TOWARD ENGINEERED PULP REGENERATION

The biological variability and limited control inherent in current cell-homing RETs have stimulated interest in more directed strategies based on the transplantation of defined stem or progenitor cell populations.[26,28] Whereas conventional RETs largely depend on recruitment of endogenous cells from periapical tissues, engineered pulp regeneration seeks greater control over the identity, number, differentiation, and spatial organization of the cells that ultimately populate the root canal.[26,28] Dental and craniofacial tissues provide several potentially useful cell sources, including dental pulp stem cells (DPSCs), stem cells from human exfoliated deciduous teeth, stem cells from the apical papilla, periodontal ligament stem cells, and progenitor populations derived from the dental follicle.[12]

DPSCs isolated from permanent teeth exhibit clonogenicity, self-renewal, and the capacity to differentiate toward odontogenic and other mesenchymal phenotypes under appropriate experimental conditions.[27]

Their origin within the pulp makes them particularly relevant to strategies intended to reconstruct pulp-like connective tissue and generate odontoblast-like cells capable of interacting with dentin [28]. Stem cells from human exfoliated deciduous teeth also demonstrate substantial proliferative and differentiation capacity and are attractive because naturally exfoliating primary teeth may provide a comparatively accessible source of autologous cells.[11] Stem cells from the apical papilla are especially relevant to regeneration of immature permanent teeth because they are closely associated with developing roots, possess substantial proliferative and odontogenic potential, and are anatomically positioned adjacent to the open apex through which endogenous cells may enter the canal.[19]

These cell populations can be incorporated into two fundamentally different regenerative strategies: cell homing and cell transplantation.[27] Cell-homing approaches seek to recruit endogenous stem or progenitor cells into the canal by creating a favorable microenvironment and providing appropriate chemotactic and biological signals.[19] This strategy has important clinical advantages because it avoids *ex vivo* cell isolation, expansion, manipulation, and transplantation. Its principal limitation, however, is reduced control over the identity, number, distribution, and differentiation of the cells that enter the canal.[6] Consequently, the resulting tissue may support healing and continued root maturation without reproducing the architecture of native dental pulp.

Cell-transplantation strategies, in contrast, introduce selected cells that have been isolated, expanded, characterized, and potentially preconditioned before implantation into the root canal.[28] In principle, this approach provides greater control over cell phenotype, number, viability, and regenerative potential and may permit more deliberate reconstruction of pulp-like tissue.[29] However, the increased biological control is accompanied by substantial translational challenges, including cell sourcing, isolation and expansion, maintenance of cellular phenotype and potency, contamination control, manufacturing standardization, storage and transportation, immunological considerations, regulatory requirements, cost, and demonstration of long-term safety and clinical effectiveness.[5] Thus, the greater biological precision offered by cell transplantation including cells sourced from a stem-cell bank, is accompanied by substantially greater clinical and logistical complexity.[11]

Importantly, the presence of viable stem or progenitor cells within the canal is only the starting point for engineered pulp regeneration.[7] A functional pulp-dentin complex requires appropriate interactions among cells, extracellular matrix, signaling molecules, blood vessels, nerves, immune components, and the surrounding dentin.[5] Cells must survive within a suitable three-dimensional scaffold, proliferate and differentiate in response to spatially and temporally regulated signals, and organize into tissue that approximates the architecture of the native pulp.[28] At the dentin-pulp interface, odontoblast-like cells would need to align along the canal walls and establish a functional relationship with dentin, while the central tissue would require a vascularized connective tissue compartment capable of maintaining cellular viability, immune surveillance, and tissue homeostasis.[28]

SCAFFOLDS, SIGNALING MOLECULES, VASCULARIZATION, AND INNERVATION

The anatomical architecture of the root canal presents distinctive challenges for tissue engineering, because the canal is a narrow, enclosed, and irregularly shaped space surrounded by mineralized dentin, with vascular and neural access occurring primarily through the apical region.[5] A scaffold intended for pulp regeneration must therefore do more than provide passive structural support.[26] Ideally, it should be biocompatible and biodegradable, permit cellular attachment, migration, proliferation, and extracellular matrix deposition, facilitate vascular and neural ingrowth, and provide or deliver biological signals that guide tissue organization.[26] Injectable scaffolds are particularly attractive because they can conform to the complex three-dimensional geometry of the root canal while minimizing the need for additional instrumentation and removal of dentin.[5]

Scaffold materials may be broadly derived from natural, synthetic, or hybrid systems, each offering distinct biological and engineering advantages.[26] Natural materials such as fibrin and collagen generally provide favorable biocompatibility and cell-interactive properties that resemble components of native extracellular matrix.[26] The blood clot used in conventional regenerative endodontic procedures represents the simplest endogenous example of such a scaffold.[7] Platelet-rich plasma and platelet-rich fibrin extend this concept by combining a fibrin-based matrix with concentrated platelets and endogenous signaling molecules.[6] Synthetic and hybrid hydrogels, in contrast, can be engineered with greater control over properties such as porosity, degradation rate, mechanical behavior, cell adhesion, and release of bioactive molecules.[4] The optimal scaffold would ideally combine the biological responsiveness of natural extracellular matrix with the reproducibility and tunability of engineered biomaterials.[5]

Scaffold architecture alone, however, cannot determine the fate of recruited or transplanted cells.[28] Signaling molecules regulate cell migration, survival, proliferation, differentiation, angiogenesis, extracellular matrix production, and tissue organization.[19] Transforming growth factor beta, bone morphogenetic proteins, vascular endothelial growth factor, fibroblast growth factors, platelet-derived growth factor, and other signaling pathways have therefore been investigated for their potential roles in pulp-dentin regeneration.[19] Dentin itself may also function as a reservoir of bioactive molecules incorporated into the extracellular matrix during tooth development and subsequently released or exposed through appropriate canal conditioning.[15] The regenerative microenvironment may consequently derive signals from multiple sources, including dentin, blood, platelets, surrounding tissues, transplanted cells, and engineered delivery systems.[15]

The principal challenge is not simply to provide growth factors but to reproduce their appropriate concentration, temporal sequence, and spatial distribution. Dental tissue development *in vivo* is regulated by dynamic signaling gradients rather than by uniform exposure to a single molecule.[31] Excessive, insufficient, or poorly timed signaling may produce unintended cellular responses or inappropriate mineralization. Engineered delivery systems are therefore being investigated to provide controlled, sequential, or spatially localized release of bioactive molecules.[27] Such approaches may eventually permit different regions of a regenerative construct to receive distinct biological instructions, promoting odontoblast-like differentiation along dentinal surfaces while supporting vascularized connective tissue formation within the central pulp space.

Among the requirements for successful pulp regeneration, vascularization is particularly critical.[5] Cells within a newly forming tissue require continuous delivery of oxygen and nutrients and removal of metabolic waste.[5] Diffusion alone can support cells only across relatively short distances, making rapid establishment of a functional microvascular network essential for survival of cells located deeper within an engineered pulp construct.[5] This problem is amplified by root canal anatomy because vascular access is largely restricted to the apical region.[5] The challenge is especially pronounced in mature teeth, where the apical foramen provides a relatively narrow pathway for vascular invasion. Immature permanent teeth, by contrast, possess a wider apical opening and therefore provide a more favorable anatomical environment for vascular ingrowth.

Multiple strategies are being investigated to overcome this vascular limitation. These include delivery of angiogenic growth factors, incorporation of endothelial or endothelial-supporting cells, development of pre-vascularized tissue constructs, use of scaffolds designed to promote vessel formation, and application of oxygen-releasing or oxygen-generating biomaterials capable of supporting cell survival during the interval before a functional circulation becomes established.[5] Ultimately, however, newly formed vessels must not merely enter the canal but develop into a stable microcirculatory network capable of integrating with the host vasculature and supporting long-term tissue homeostasis.

Innervation represents another essential component of complete biological regeneration.[5] The native dental pulp contains an extensive sensory and autonomic neural network that contributes to nociception, neurovascular regulation, inflammatory responses, and tissue homeostasis.[5] Restoration of pulp-like tissue without neural integration may therefore reproduce some biological functions while failing to restore others.[29] Experimental studies have demonstrated that neural ingrowth into regenerated or engineered pulp-like tissues is possible, but predictable reconstruction of an organized and functionally integrated neurovascular architecture remains a substantial challenge.[6] Moreover, vascularization and innervation should not be considered entirely independent processes because blood vessels and nerves interact during development, repair, and tissue homeostasis.

DENTAL STEM-CELL BANKING AND ITS TRANSLATIONAL SIGNIFICANCE

The identification of stem and progenitor cell populations within dental tissues has generated substantial research and commercial interest in dental stem-cell banking.[11] Teeth that would otherwise be discarded, particularly naturally exfoliated deciduous teeth and

extracted third molars, can provide pulp and other dental tissues from which viable stem or progenitor cells may be isolated, expanded, characterized, and cryopreserved for potential future use.[11] This possibility has created a conceptual link between routine dental care and the emerging field of personalized regenerative medicine.

Interest in this approach appears to extend beyond the research community. In one survey, although only 14% of participants reported previous use of umbilical cord or other stem-cell banking for themselves or a relative, 63% believed that stem-cell banking could be useful for regeneration of dental tissues, and 89% indicated that they would be willing to preserve teeth or dental tissues for stem-cell banking.[32] These findings suggest substantial public interest in the concept of preserving dental tissues for possible future therapeutic applications. They do not, however, establish that dental stem-cell banking currently provides a proven clinical benefit.

The biological rationale for banking DPSCs is nevertheless compelling.[32] DPSCs collected from younger individuals may possess favorable proliferative and regenerative characteristics, and cryopreservation could theoretically provide an autologous cell source for future therapies.[33] If cell-based pulp regeneration or other dental tissue-engineering strategies ultimately become established clinically, previously banked DPSCs might offer advantages by providing a readily identifiable source of patient-derived biological material.[32] In principle, autologous cells could also reduce some of the immunological concerns associated with allogeneic transplantation.

The ability to isolate and cryopreserve viable cells, however, should be distinguished carefully from demonstration of clinical utility.[33] The value of banking ultimately depends on whether future regenerative therapies require the stored cell population, whether enough therapeutically competent DPSCs can be recovered after prolonged cryopreservation, and whether those cells retain appropriate viability, proliferative capacity, differentiation potential, genetic stability, and functional characteristics. [33] Its value will also depend on whether comparable or superior autologous, allogeneic, or induced cell sources can be obtained when treatment is eventually required. Most importantly, the rationale for long-term storage depends on the eventual development of validated cell-based therapies that demonstrate sufficient safety, efficacy, reproducibility, and clinical benefit to justify use of the banked DPSCs.[11]

Long-term DPSC banking also raises important technical, regulatory, economic, and ethical considerations.[32] Reliable banking requires standardized procedures for tissue collection, transportation, cell isolation, processing, characterization, cryopreservation, storage, and eventual recovery.[11] Quality-control systems must minimize microbial contamination, confirm cell identity and viability, and address the possibility of genetic or epigenetic changes during processing, expansion, or prolonged storage.[32] Because stored biological material may remain in repositories for decades, questions also arise regarding ownership, informed consent, privacy, transfer of control when samples are collected from children, duration of storage, financial responsibility, institutional failure, and disposition of samples that are no longer wanted or usable.

Caution is warranted in communicating the potential benefits of banking to patients and parents.[32] The possibility that DPSCs may become useful for future regenerative therapies is scientifically plausible, but potential future applications should not be presented as established indications or guaranteed therapeutic opportunities. Commercial

availability of a banking service does not itself demonstrate that the stored DPSCs will eventually be required, clinically useful, or superior to cell sources available at the time treatment is needed.[11] A clear distinction between demonstrated capabilities, investigational applications, and speculative future uses is therefore essential to meaningful informed consent.

DPSC banking should consequently be regarded as a developing translational technology rather than an established therapeutic necessity.[11] Its present scientific value lies in the ability to preserve potentially useful biological material and support research into future cell based RETs. Its ultimate clinical value, however, will depend on successful translation of regenerative technologies that can make meaningful therapeutic use of those cells.[32] Until such therapies are validated, the strong interest in DPSC banking should be interpreted as evidence of enthusiasm for regenerative medicine rather than evidence that routine banking currently improves clinical outcomes.

STEM-CELL-BASED PULP REGENERATION AND FUTURE TISSUE ENGINEERING

Stem-cell-based pulp regeneration represents a more ambitious objective than current RETs because it seeks the deliberate reconstruction of pulp-like tissue using defined and controllable biological components.[5] Whereas contemporary cell-homing procedures largely depend on recruitment of endogenous cells and the intrinsic healing capacity of periapical tissues, cell-based tissue engineering attempts to direct the regenerative process through selection of specific cells, scaffolds, signaling molecules, and delivery strategies.[26,28] In principle, an appropriate stem or progenitor cell population could be isolated, expanded, and characterized under controlled conditions, incorporated into a biocompatible three-dimensional scaffold containing selected biological signals, and introduced into a disinfected root canal. Successful RET would then require the implanted cells to survive, integrate with host tissues, establish a functional vascular supply, acquire appropriate neural connections, and differentiate into spatially organized populations capable of reproducing essential functions of the native pulp-dentin complex.

Some experimental studies support the biological plausibility of this RET approach. Under appropriate conditions, DPSC and progenitor cells can contribute to formation of vascularized pulp-like connective tissue and differentiate toward odontoblast-like phenotypes associated with mineralized tissue deposition.[5] Such findings provide proof of principle that components of the pulp-dentin complex can be reconstructed experimentally.[34] Formation of pulp-like tissue in an experimental model, however, does not by itself establish that the same strategy can be translated into a predictable, durable, and clinically practical treatment in humans.

Clinical translation requires resolution of substantial interconnected challenges.[5] Cell-based therapies require reliable sources of therapeutically competent DPSCs together with standardized methods for isolation, expansion, characterization, storage, transportation, and delivery.[26] Manufacturing processes must maintain sterility, cellular identity, potency, genetic stability, and reproducibility while satisfying regulatory requirements applicable to living biological products.[35] Autologous approaches may reduce certain immunological concerns but require individualized cell procurement and manufacturing, whereas allogeneic approaches may facilitate standardization and scalability but introduce additional questions regarding immune compatibility and donor

variability.[11] These considerations must ultimately be balanced against treatment complexity, cost, accessibility, long-term safety, and demonstrable clinical benefit over existing therapies.

Future RETs, however, may not require transplantation of intact DPSCs.[26] Increasing attention is being directed toward cell-free RETs that seek to activate endogenous repair through extracellular vesicles, stem-cell secretomes, chemotactic molecules, bioactive matrices, and controlled delivery of growth factors and other signaling molecules.[6] Because many therapeutic effects attributed to transplanted stem cells may result partly from paracrine signaling rather than permanent cellular engraftment, cell-free approaches could potentially reproduce selected regenerative effects while reducing some of the manufacturing, storage, immunological, and regulatory complexities associated with living cell products.[6] Their effectiveness will nevertheless depend on achieving sufficiently controlled and durable biological signaling within the root canal microenvironment.

Advances in scaffold biomaterials and bio-fabrication may provide additional control over tissue architecture.[34] Three-dimensional bioprinting, advanced injectable hydrogels, biomimetic extracellular matrices, organoid-based systems, and spatially controlled delivery of biological signals offer potential strategies for reproducing aspects of the heterogeneous organization of native pulp.[5] Rather than generating a uniform mass of undifferentiated connective tissue, future RET constructs may be designed to establish an odontoblast-like layer at the dentinal interface, vascular and neural networks within the pulp core, and functional communication with tissues at the apical foramen.[34] Such spatial organization will be essential if engineered tissue is expected to reproduce pulp physiology rather than merely occupy the canal.

Emerging gene-regulatory and molecular approaches may further increase control over regenerative responses by modulating pathways involved in cell recruitment, angiogenesis, neurogenesis, odontogenic differentiation, inflammation, and extracellular matrix formation.[5] These technologies could potentially allow regenerative signals to be delivered with greater spatial and temporal precision. However, increasing biological control also introduces additional safety concerns, particularly regarding unintended differentiation, ectopic mineralization, persistent alterations in gene expression, and long-term effects that may not become apparent during short experimental observation periods.[35]

The future of RETs is therefore likely to involve convergence among stem-cell biology, biomaterials science, molecular signaling, vascular and neural engineering, and advanced bio-fabrication rather than reliance on any single regenerative component. Whether the optimal clinical strategy ultimately involves transplanted cells, endogenous cell homing, cell-free biological products, engineered scaffolds, or combinations of these approaches remains uncertain. The appropriate benchmark for progress should therefore extend beyond the demonstration that living tissue can be generated within a root canal.[34]

INTEGRATING CONTEMPORARY REGENERATIVE ENDODONTIC TREATMENT (RET) STRATEGIES

Contemporary RETs are best understood as a biologically integrated continuum rather than as competing techniques. RET selection should account for pulpal and periapical status, root

maturity, microbial contamination, remaining tooth structure, restorative prognosis, and the probability of healing. The preferred intervention is not necessarily the newest procedure, but the least destructive approach capable of achieving predictable disease control while retaining the greatest feasible biological function.

When viable DPSCs retains healing potential, conservative caries management and vital pulp therapy offer the most direct means of preserving its vascular, neural, immune, and dentinogenic functions.[6] The extent of treatment can be matched to the distribution of injury: indirect pulp treatment avoids unnecessary exposure, direct pulp capping protects selected exposures, and partial or complete pulpotomy removes increasingly extensive compromised coronal tissue while retaining viable pulp. In immature permanent teeth, preserving radicular and apical tissues also protects the capacity for apexogenesis.[7]

When pulpal necrosis has occurred, treatment priorities change.[2] Conventional root canal therapy remains an established means of infection control and tooth retention, while apexification provides an apical barrier in immature teeth with open apices. Selected necrotic immature teeth may instead benefit from RETs intended to support intracanal tissue formation and further root maturation.[5] Such benefits should be assessed on their clinical and developmental merits without presuming histological regeneration of native pulp.

Engineered cell-based and cell-free approaches aim to advance beyond endogenous repair toward organized reconstruction of the pulp-dentin complex.[34] Their biological promise must be weighed against manufacturing complexity, regulatory requirements, cost, safety, and the demonstrated effectiveness of established treatments.[35] Thus, the organizing principle is not that biological ambition should always supersede conventional care, but that each intervention should offer an evidence-supported advantage appropriate to the condition of the tooth.[7]

This continuum places preservation first when native tissue can predictably recover, disease control and repair when it cannot, and engineered RET where restoration of lost function could provide a meaningful clinical benefit.[5] RETs strength lies in integrating established and emerging options without conflating biological potential with proven clinical superiority.

CHALLENGES AND FUTURE DIRECTIONS

The continued development of biologically based RETs will depend on overcoming several interconnected diagnostics, biological, technological, and translational challenges. Progress will require not only improvements in regenerative technologies but also greater precision in determining when native pulp can be preserved, when repair or revitalization is biologically achievable, and when more advanced regenerative intervention is justified. The future of RET therefore depends as much on improved patient and case selection[7] as on the development of new biomaterials, cells, and tissue-engineering strategies.

Accurate assessment of pulpal status remains a fundamental challenge.[2] Successful vital pulp therapy depends on identifying tissue that retains sufficient viability and healing potential, yet current clinical diagnostic categories rely largely on patient-reported symptoms, clinical examination, radiographic findings, and responses to sensibility testing.[7] These measures provide clinically useful but indirect information about the location, extent,

and reversibility of pulpal inflammation and do not necessarily correspond precisely with histopathological findings. The development of objective molecular or biological markers capable of characterizing pulpal inflammation, tissue viability, microbial burden, and regenerative potential could permit more precise discrimination between tissue that requires removal and tissue that can predictably recover.[5] Such diagnostics could shift treatment selection from symptom-based categories toward biologically individualized assessment.

Microbial leakage prevention and its removal, remains equally important for the success of RET.[5] Newly recruited or transplanted cells cannot survive and organize predictably in an environment containing persistent pathogenic microorganisms and inflammatory microbial products.[5] At the same time, antimicrobial strategies must preserve the biological properties required for regeneration.[28] Excessively aggressive instrumentation may weaken dentinal walls and alter the intracanal microenvironment, while cytotoxic concentrations of irrigants or medicaments may impair progenitor-cell survival, disrupt dentin-derived signaling molecules, or interfere with cellular attachment and differentiation. [28] Future protocols must therefore achieve a carefully calibrated balance between antimicrobial effectiveness and preservation of regenerative capacity.

Translation of increasingly complex RET technologies into routine clinical practice presents another major challenge. Cell-based therapies, engineered scaffolds, extracellular vesicles, growth-factor delivery systems, gene-regulatory approaches, and advanced bio-fabrication technologies must demonstrate not only biological efficacy but also safety, reproducibility, manufacturability, scalability, regulatory acceptability, cost-effectiveness, and practical clinical feasibility.[35] A therapy that produces sophisticated pulp-like tissue experimentally may have limited clinical value if it requires prohibitively complex manufacturing, specialized infrastructure, or costs disproportionate to its benefits. Future RET strategies must therefore be evaluated against established treatments rather than solely against experimental controls.

The long-term safety and biological stability of RETs will also require careful evaluation. RETs that manipulate cell proliferation, differentiation, angiogenesis, or gene expression may produce hazards that are not evident during short follow-up periods. Potential concerns include inappropriate mineralization, canal obliteration, uncontrolled cellular differentiation, inflammatory responses, loss of regenerated tissue, and failure of newly formed tissue to maintain function over time.[35] Demonstrating initial tissue formation is therefore insufficient; regenerated tissues must remain biologically stable, functionally integrated, and clinically beneficial over clinically meaningful periods.

The outcome assessment of RETs must evolve alongside these technologies. The resolution of pain, swelling, and apical radiolucency represents successful disease control, while increased root length, dentinal wall thickness, and apical maturation represent important developmental outcomes.[5,7] Recovery of responsiveness to sensibility testing may provide evidence of viable and potentially innervated tissue. None of these outcomes, however, independently demonstrates restoration of native pulp histology or function. Future clinical studies should therefore distinguish among disease resolution, tissue repair, revitalization, continued root development, functional recovery, and true regeneration rather than combining these biologically different endpoints under a single definition of success.

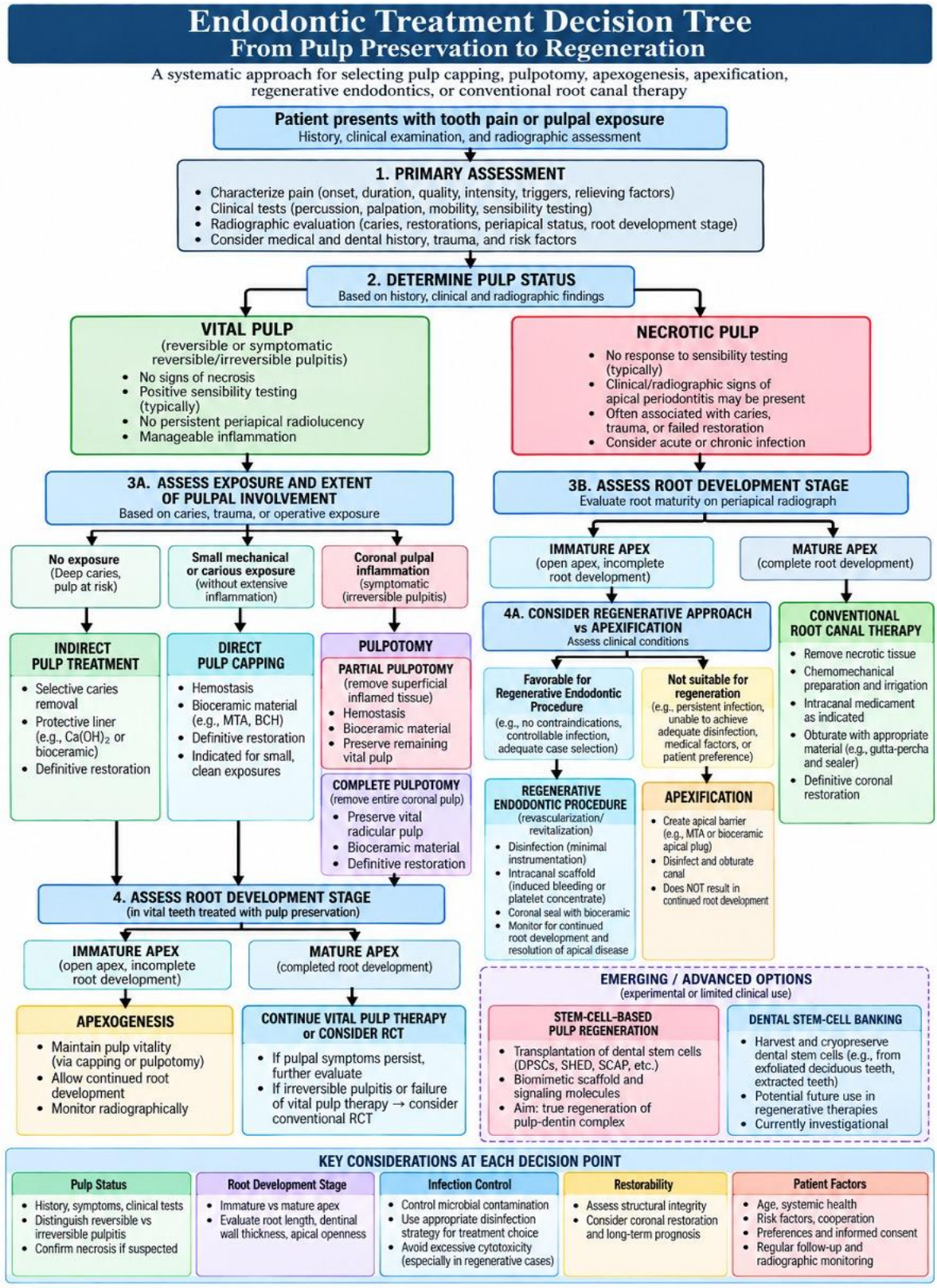

Figure 1

Improved methods for assessing RET tissue *in vivo* will be particularly important because histological evaluation is rarely feasible in successfully treated human teeth.[35] Noninvasive imaging, quantitative assessment of pulpal blood flow, improved neural or

sensory testing, molecular biomarkers, and other functional measures may eventually permit more direct evaluation of tissue identity and biological performance without sacrificing the treated tooth. Standardized RET outcome definitions and longer follow-up periods will also be necessary to compare different RETs reliably across clinical studies.

Ultimately, the most meaningful advance may be a transition from procedure-based endodontics toward biologically individualized RETs, in which the therapy is selected according to the actual condition and regenerative potential of the pulp-dentin complex.[7] Such an approach would prioritize preservation of native tissue whenever possible, promote repair or revitalization when preservation is no longer achievable, and reserve increasingly complex RETs for circumstances in which reconstruction of lost tissue offers a meaningful clinical advantage.

The RET and endodontic treatment decision tree, summarizing the previously discussed evidence is shown in Figure 1 overleaf.

CONCLUSION

Contemporary endodontics is evolving from an exclusive emphasis on removing diseased tissue and preventing reinfection toward a more comprehensive RET objective: preserving or restoring the biological functions of the pulp-dentin complex whenever clinically feasible. Conventional root canal treatment remains indispensable for predictable infection control and long-term tooth retention. Nevertheless, advances in pulpal biology demonstrate that inflamed pulp may retain meaningful healing potential, supporting a more selective approach to tissue removal.

Vital pulp therapy provides the clearest expression of this principle. Indirect pulp treatment, direct pulp capping, partial pulpotomy, and complete pulpotomy preserve varying amounts of native tissue according to the extent of disease and the likelihood of healing. In immature permanent teeth, successful preservation can also sustain apexogenesis, allowing continued root elongation, dentinal wall thickening, and apical maturation. Where necrosis has interrupted development, apexification permits management of the open apex, while regenerative endodontic procedures may support intracanal tissue formation and further root maturation in selected cases.

The interpretation of RET outcomes requires biological precision. Revascularization establishes vascular ingrowth, revitalization indicates living tissue within a previously necrotic canal, and repair may restore clinical health through tissue that differs from the original pulp. True regeneration requires reconstruction of the essential architecture and functions of the native pulp-dentin complex, including vascular, neural, immune, and dentinogenic activity. Clinical healing and continued root development are valuable outcomes, but neither alone demonstrates complete pulp regeneration.

DPSCs and progenitor cells, advanced scaffolds, signaling molecules, extracellular vesicles, and vascular and neural engineering offer promising routes toward that more demanding objective. DPSC banking may eventually support some cell-based applications, although its clinical utility depends on the development of validated therapies that benefit from stored cells. Across these emerging technologies, biological plausibility must be translated into reproducible safety, meaningful functional recovery, long-term stability, and advantages over established care.

The future of endodontics therefore lies in delivering biologically individualized RETs rather than the wholesale replacement of conventional methods. The most defensible therapeutic sequence is to preserve recoverable native pulp, support physiological development, when possible, promote repair and revitalization when tissue has been lost, and pursue engineered RET where it can deliver demonstrable additional benefit. This integrated approach aligns scientific ambition with clinical evidence and keeps the preservation of natural tooth structure and function at the center of care.

Disclosure

The authors did not report any disclosures.

REFERENCES

1. Epelman I, Murray PE, Garcia-Godoy F, Kuttler S, Namerow KN. A practitioner survey of opinions toward regenerative endodontics. J Endod. 2009;35(9):1204-1210. doi:10.1016/j.joen.2009.04.059
2. Trope M. Regenerative potential of dental pulp. Pediatr Dent. 2008;30(3):206-210.
3. López-Valverde I, Vignoletti F, Vignoletti G, Martin C, Sanz M. Long-term tooth survival and success following primary root canal treatment: a 5- to 37-year retrospective observation. Clin Oral Investig. 2023;27(6):3233-3244. doi:10.1007/s00784-023-04938-y
4. Levine M. Root-canal therapy: a means of treating oral pain and infection. Can Fam Physician. 1988;34:1357-1365.
5. Murray PE, Garcia-Godoy F, Hargreaves KM. Regenerative endodontics: a review of current status and a call for action. J Endod. 2007;33(4):377-390. doi:10.1016/j.joen.2006.09.013.
6. Murray PE. Platelet-rich plasma and platelet-rich fibrin can induce apical closure more frequently than blood-clot revascularization for the regeneration of immature permanent teeth: A meta-analysis of clinical efficacy. Front Bioeng Biotechnol. 2018;6:139. doi:10.3389/fbioe.2018.00139.
7. Garcia-Godoy F, Murray PE. Recommendations for using regenerative endodontic procedures in permanent immature traumatized teeth. Dent Traumatol. 2012;28(1):33-41. doi:10.1111/j.1600-9657.2011.01044.x.
8. Murray PE. Review of guidance for the selection of regenerative endodontics, apexogenesis, apexification, pulpotomy, and other endodontic treatments for immature permanent teeth. Int Endod J. 2023;56 Suppl 2:188-199. doi:10.1111/iej.13809.
9. Driesen RB, Gervois P, Vangansewinkel T, Lambrichts I. Unraveling the role of the apical papilla during dental root maturation. Front Cell Dev Biol. 2021;9:665600. doi:10.3389/fcell.2021.665600
10. Chaipattanawan N, Chompu-Inwai P, Manmontri C, Cherdsatirakul P, Nirunsittirat A, Phinyo P. Tooth fracture and associated risk factors in permanent molars treated with vital pulp therapy and restored with direct resin composites: A retrospective survival analysis in young patients. Eur Endod J. 2023;8(1):37-46. doi:10.14744/eej.2022.18894.
11. Harris DT. Stem cell banking for regenerative and personalized medicine. Biomedicines. 2014;2(1):50-79. doi:10.3390/biomedicines2010050.
12. Mantesso A, Nör JE. Stem cells in clinical dentistry. J Am Dent Assoc. 2023;154(12):1048-1057. doi:10.1016/j.adaj.2023.08.007.

13. Murray PE, Stanley HR, Matthews JB, Sloan AJ, Smith AJ. Age-related odontometric changes of human teeth. Oral Surg Oral Med Oral Pathol Oral Radiol Endod. 2002;93(4):474-482. doi:10.1067/moe.2002.120974.

14. Murray PE, Smith AJ. Saving pulps--a biological basis. An overview. Prim Dent Care. 2002;9(1):21-26. doi:10.1308/135576102322547511.

15. Murray PE, About I, Franquin JC, Remusat M, Smith AJ. Restorative pulpal and repair responses. J Am Dent Assoc. 2001;132(4):482-491. doi:10.14219/jada.archive.2001.0211.

16. Murray PE, Lumley PJ, Hafez AA, Cox CF, Smith AJ. Preserving the vital pulp in operative dentistry: 4. Factors influencing successful pulp capping. Dent Update. 2002;29(5):225-233. doi:10.12968/denu.2002.29.5.225.

17. Smith AJ, Murray PE, Lumley PJ. Preserving the vital pulp in operative dentistry: I. A biological approach. Dent Update. 2002;29(2):64-69. doi:10.12968/denu.2002.29.2.64.

18. Murray PE, García-Godoy F. The incidence of pulp healing defects with direct capping materials. Am J Dent. 2006;19(3):171-177.

19. Howard C, Murray PE, Namerow KN. Dental pulp stem cell migration. J Endod. 2010;36(12):1963-1966. doi:10.1016/j.joen.2010.08.046.

20. Gu S, Yang Y. Clinical outcomes of vital pulp therapy versus root canal treatment in immature permanent teeth with pulpal involvement: a meta-analysis. Front Pediatr. 2026;14:1754580. doi:10.3389/fped.2026.1754580.

21. Aly YM, Bakry SI, Tuma Halabi MA. Fracture resistance and bond strength of endodontically treated teeth, restored with three fiber post and core system: an in vitro study. Sci Rep. 2025;15(1):39007. doi:10.1038/s41598-025-23778-2.

22. Lao Dee SM, Kao CY, de Leon AP, Huang TH. Managing limited clinical crown height with vital pulp therapy: Clinical application and outcome. J Dent Sci. 2025;20(3):1988-1990. doi:10.1016/j.jds.2025.04.004.

23. Pohl S, Akamp T, Smeda M, et al. Understanding dental pulp inflammation: from signaling to structure. Front Immunol. 2024;15:1474466. doi:10.3389/fimmu.2024.1474466.

24. Murray PE, Smith AJ, Windsor LJ, Mjör IA. Remaining dentine thickness and human pulp responses. Int Endod J. 2003;36(1):33-43. doi:10.1046/j.0143-2885.2003.00609.x

25. Murray PE, About I, Lumley PJ, Smith G, Franquin JC, Smith AJ. Postoperative pulpal and repair responses. J Am Dent Assoc. 2000;131(3):321-329. doi:10.14219/jada.archive.2000.0175

26. Chandrahasa S, Murray PE, Namerow KN. Proliferation of mature *ex vivo* human dental pulp using tissue engineering scaffolds. J Endod. 2011;37(9):1236-1239. doi:10.1016/j.joen.2011.05.030.

27. Murray PE, Garcia-Godoy F. Stem cell responses in tooth regeneration. Stem Cells Dev. 2004;13(3):255-262. doi:10.1089/154732804323099181.

28. Ring KC, Murray PE, Namerow KN, Kuttler S, Garcia-Godoy F. The comparison of the effect of endodontic irrigation on cell adherence to root canal dentin. J Endod. 2008;34(12):1474-1479. doi:10.1016/j.joen.2008.09.001.

29. Minic S, Vital S, Chaussain C, Boukpessi T, Mangione F. Tissue characteristics in endodontic regeneration: A systematic review. Int J Mol Sci. 2022;23(18):10534. doi:10.3390/ijms231810534.

30. Kim D, Kim SG. Cell homing strategies in regenerative endodontic therapy. Cells. 2025;14(3):201. doi:10.3390/cells14030201.

31. Bei M. Molecular genetics of tooth development. Curr Opin Genet Dev. 2009;19(5):504-510. doi:10.1016/j.gde.2009.09.002

32. Anitha K, Asoka S, Acchuthakrishnan, Dhanraj T, Arunachalam P, Arumugam S. Current Status of Knowledge, Attitude, and Perspective of Dental Practitioners Toward Stem Cell Uses in Dentistry. J Pharm Bioallied Sci. 2024;16(Suppl 5):S4800-S4803. doi:10.4103/jpbs.jpbs_1227_24

33. Choudhery MS, Arif T, Mahmood R. Aging puzzle: A closer look on the complex dilemma of autologous stem cell therapy. World J Stem Cells. 2026;18(1):114119. doi:10.4252/wjsc.v18.i1.114119.

34. Gotlieb EL, Murray PE, Namerow KN, Kuttler S, Garcia-Godoy F. An ultrastructural investigation of tissue-engineered pulp constructs implanted within endodontically treated teeth. J Am Dent Assoc. 2008;139(4):457-465. doi:10.14219/jada.archive.2008.0189.

35. Murray PE, García Godoy C, García Godoy F. How is the biocompatibilty of dental biomaterials evaluated? Med Oral Patol Oral Cir Bucal. 2007;12(3):E258-E266.